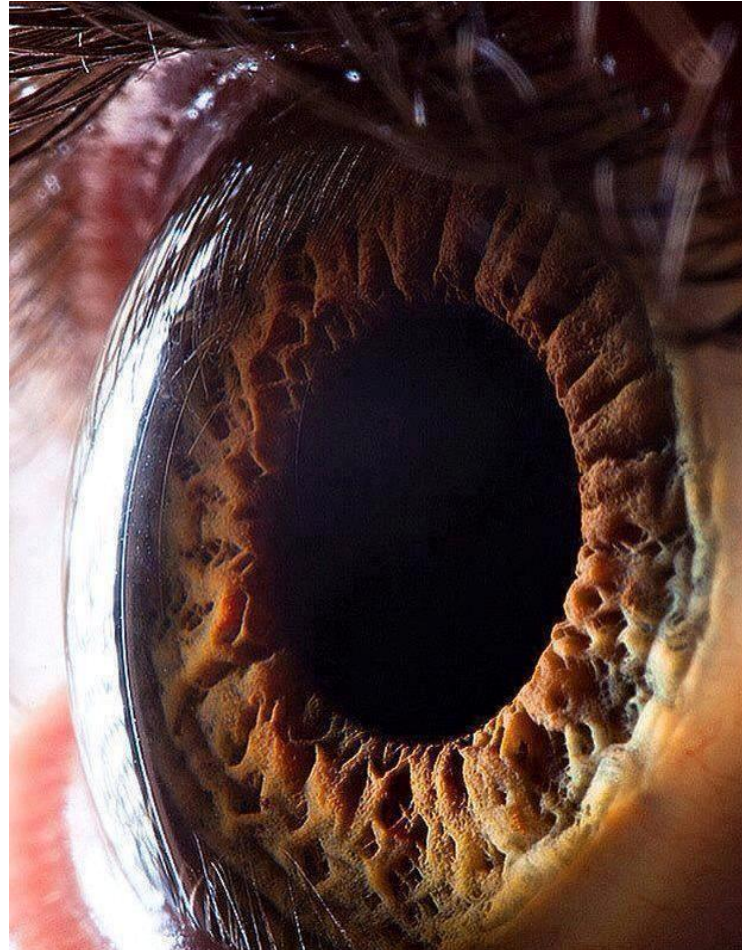


# Le cellule staminali e l'occhio

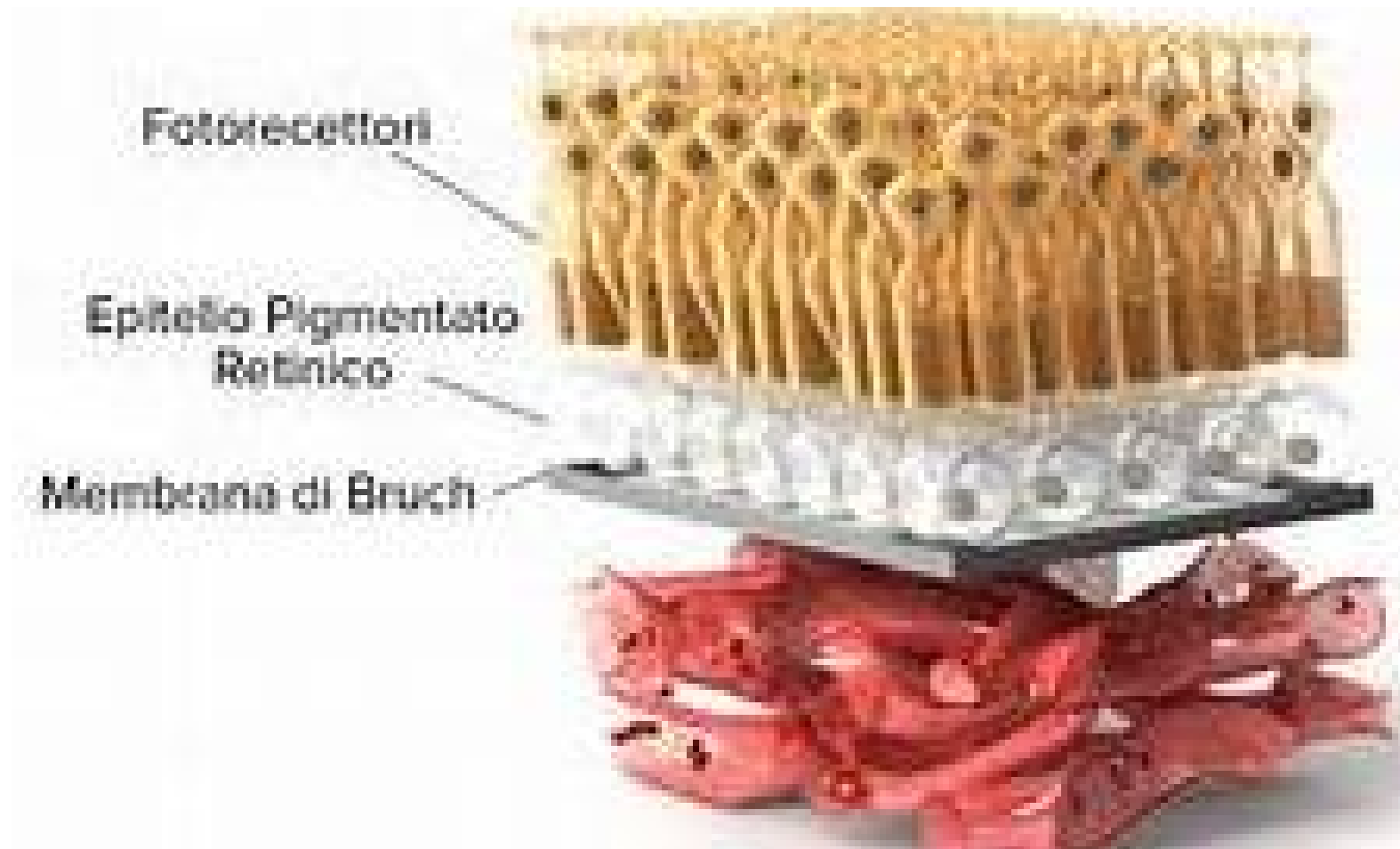


Dott Franco Arrigoni  
Responsabile UOS chirurgia  
oculistica polo H2 ASL RMH

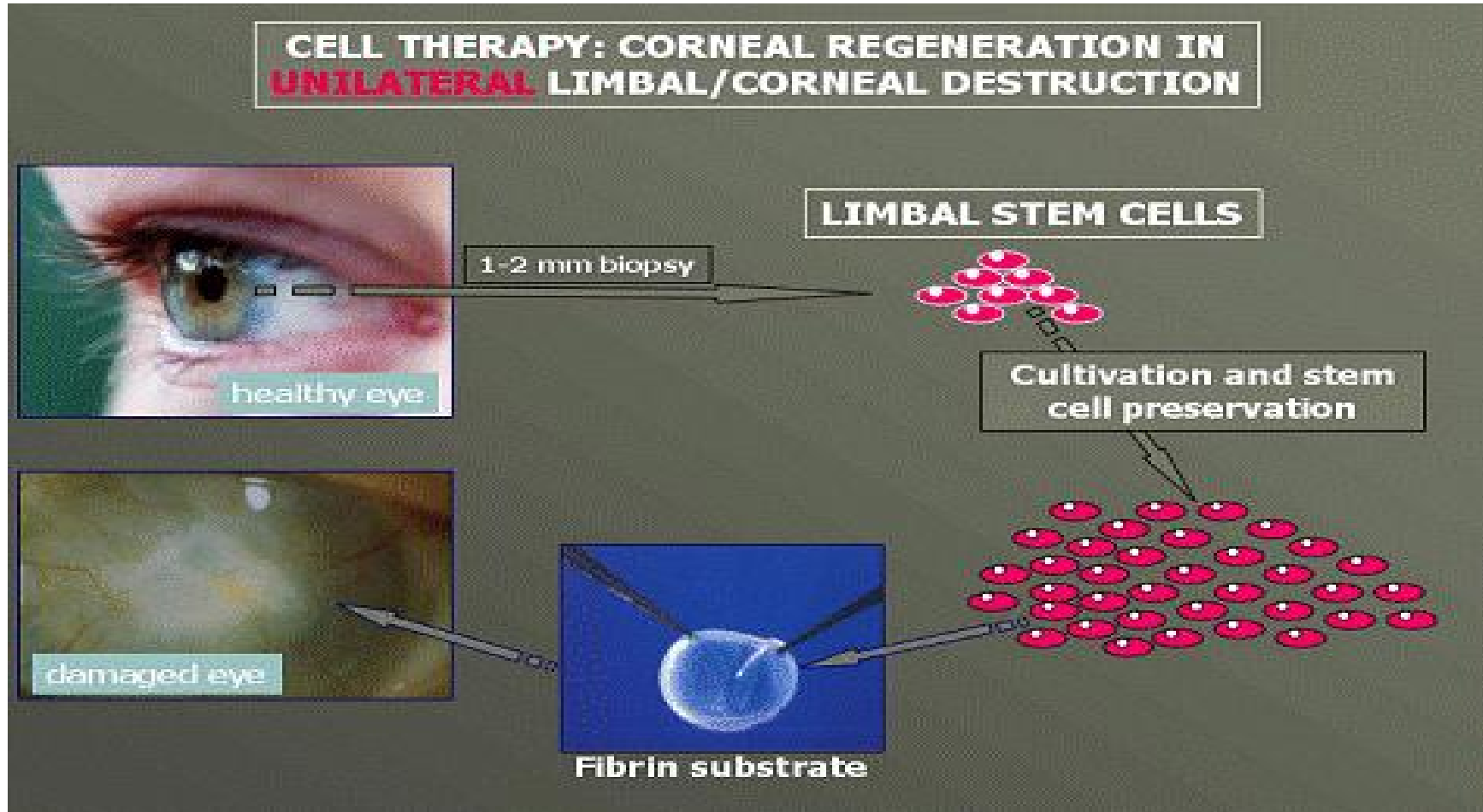
# Lente e la sua superficie



# Struttura della retina



# Processo di rigenerazione delle staminali corneali

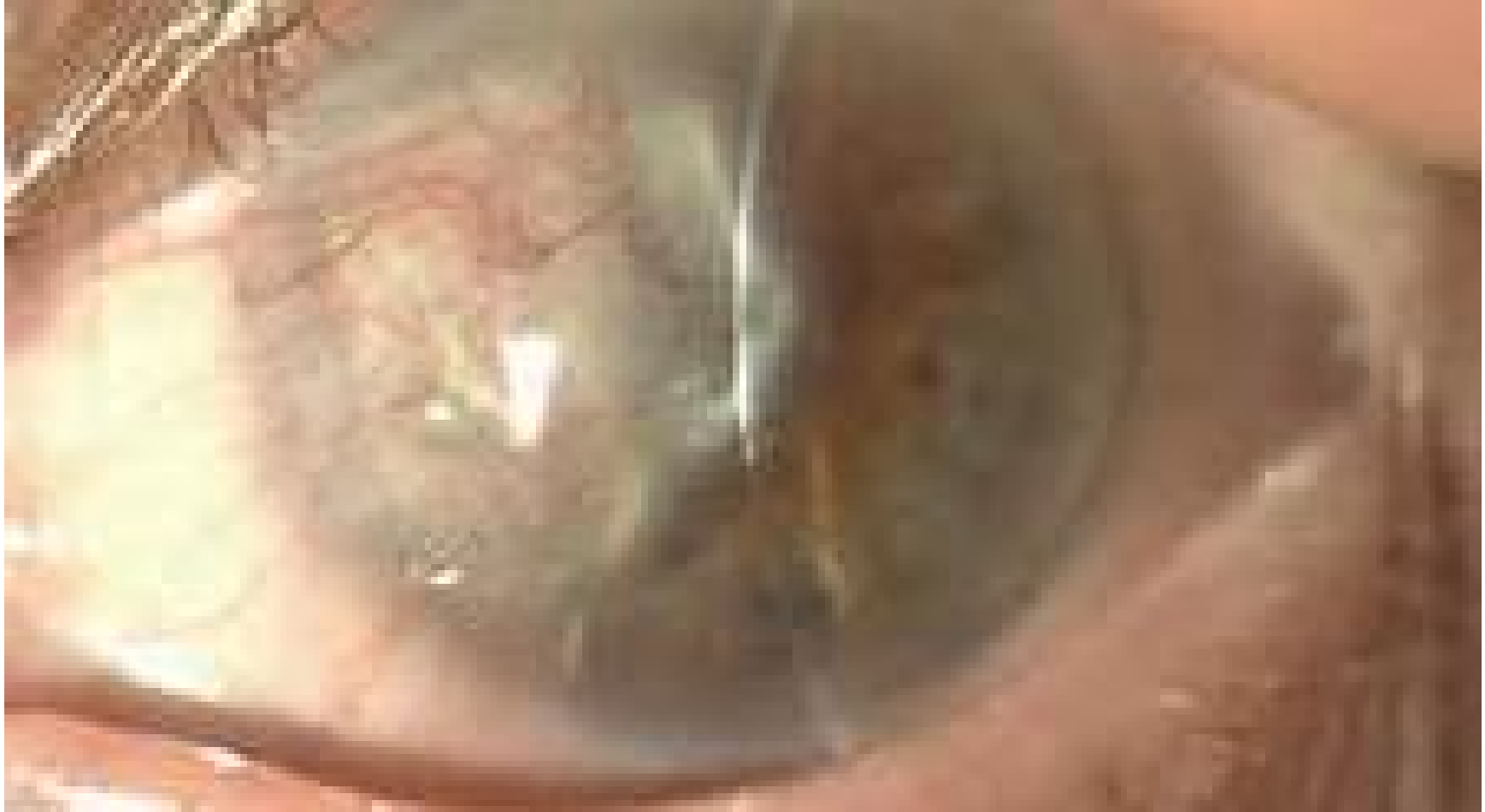



*Your complimentary  
use period has ended.  
Thank you for using  
PDF Complete.*

[Click Here to upgrade to  
Unlimited Pages and Expanded Features](#)

# compensi corneali



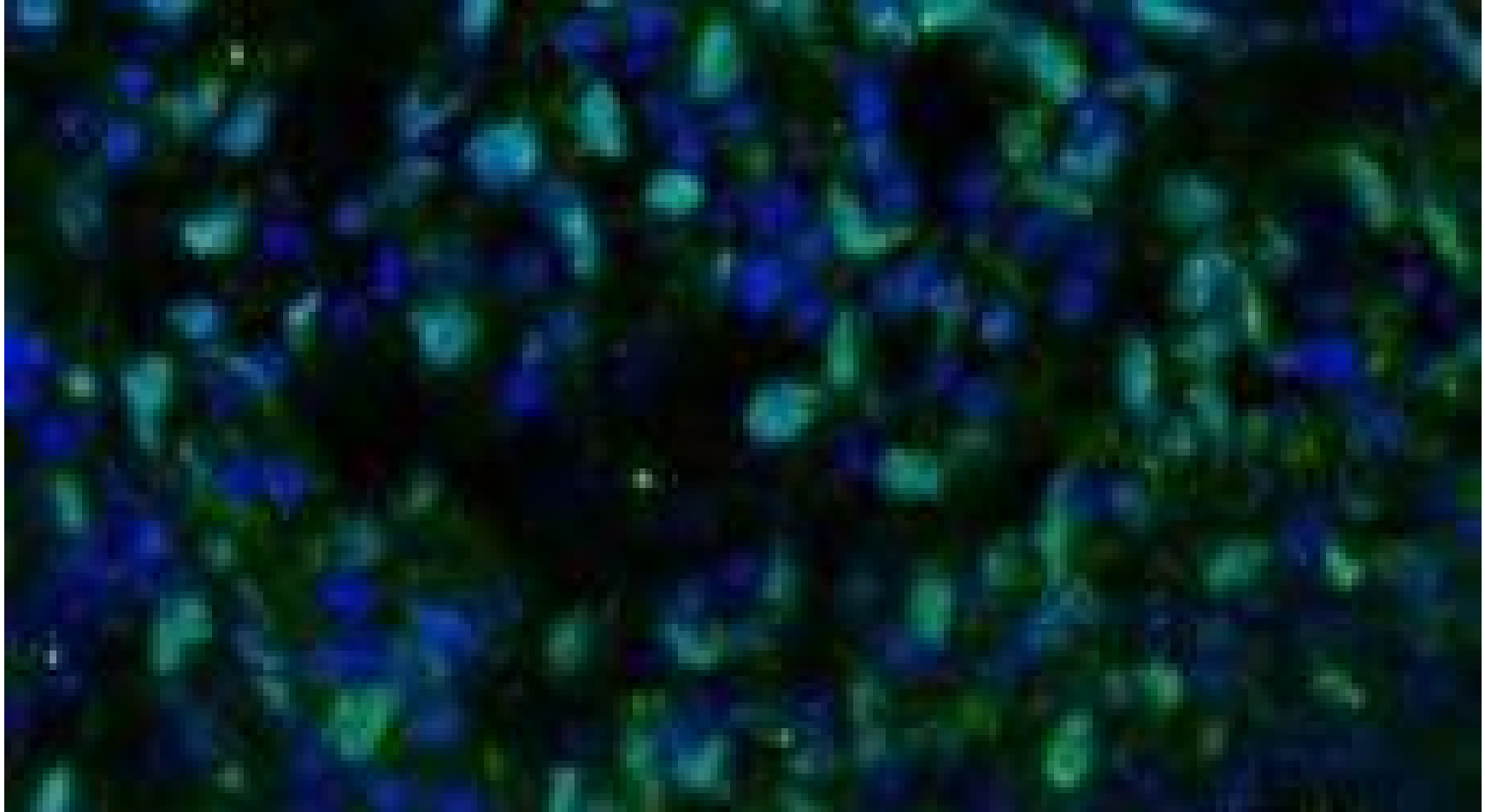
# Le nuove terapie intravitreali



# La banca degli occhi del veneto



# Staminali retiniche







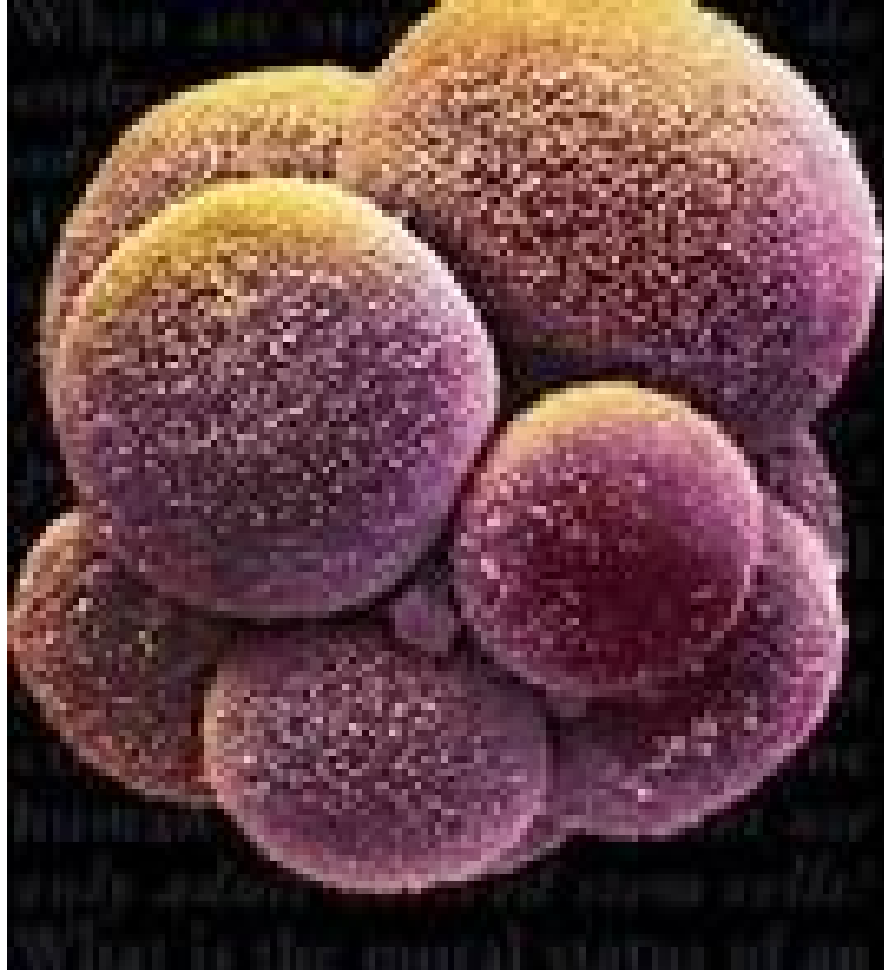*Your complimentary  
use period has ended.  
Thank you for using  
PDF Complete.*

[Click Here to upgrade to  
Unlimited Pages and Expanded Features](#)

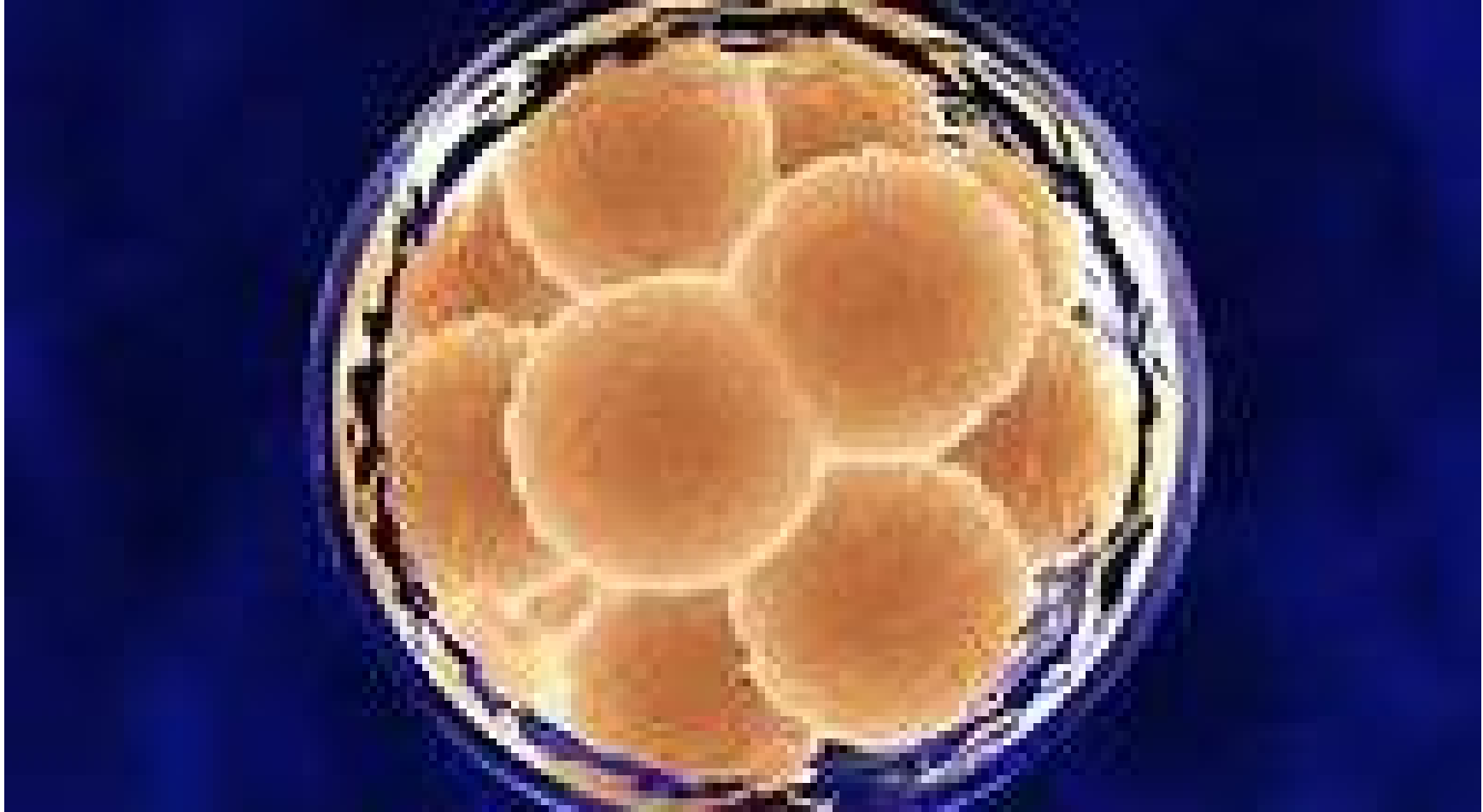# rione, la vita e l'uomo.



# Staminali embrionarie



# cellule embrionarie

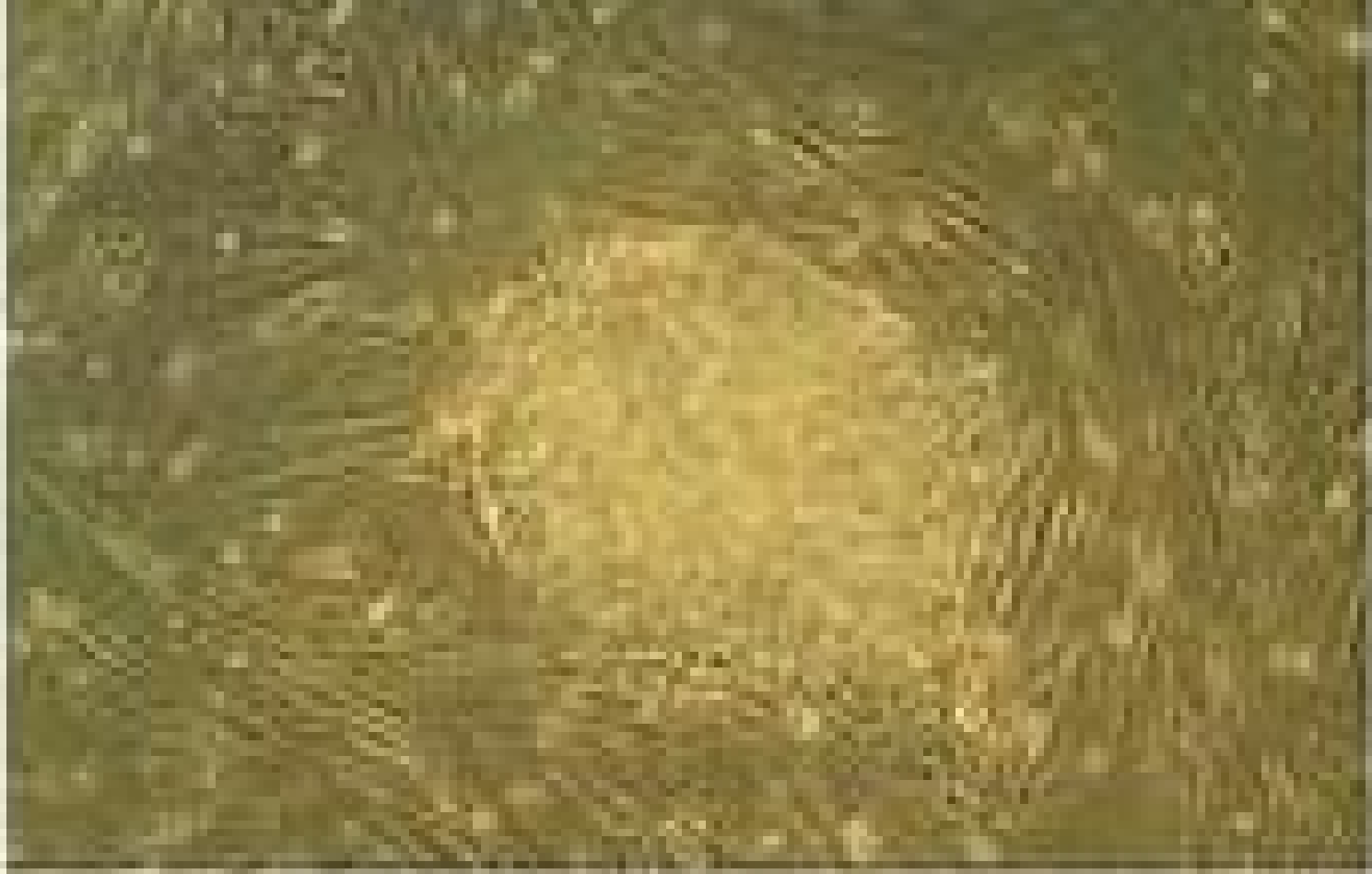




*Your complimentary  
use period has ended.  
Thank you for using  
PDF Complete.*

[Click Here to upgrade to  
Unlimited Pages and Expanded Features](#)

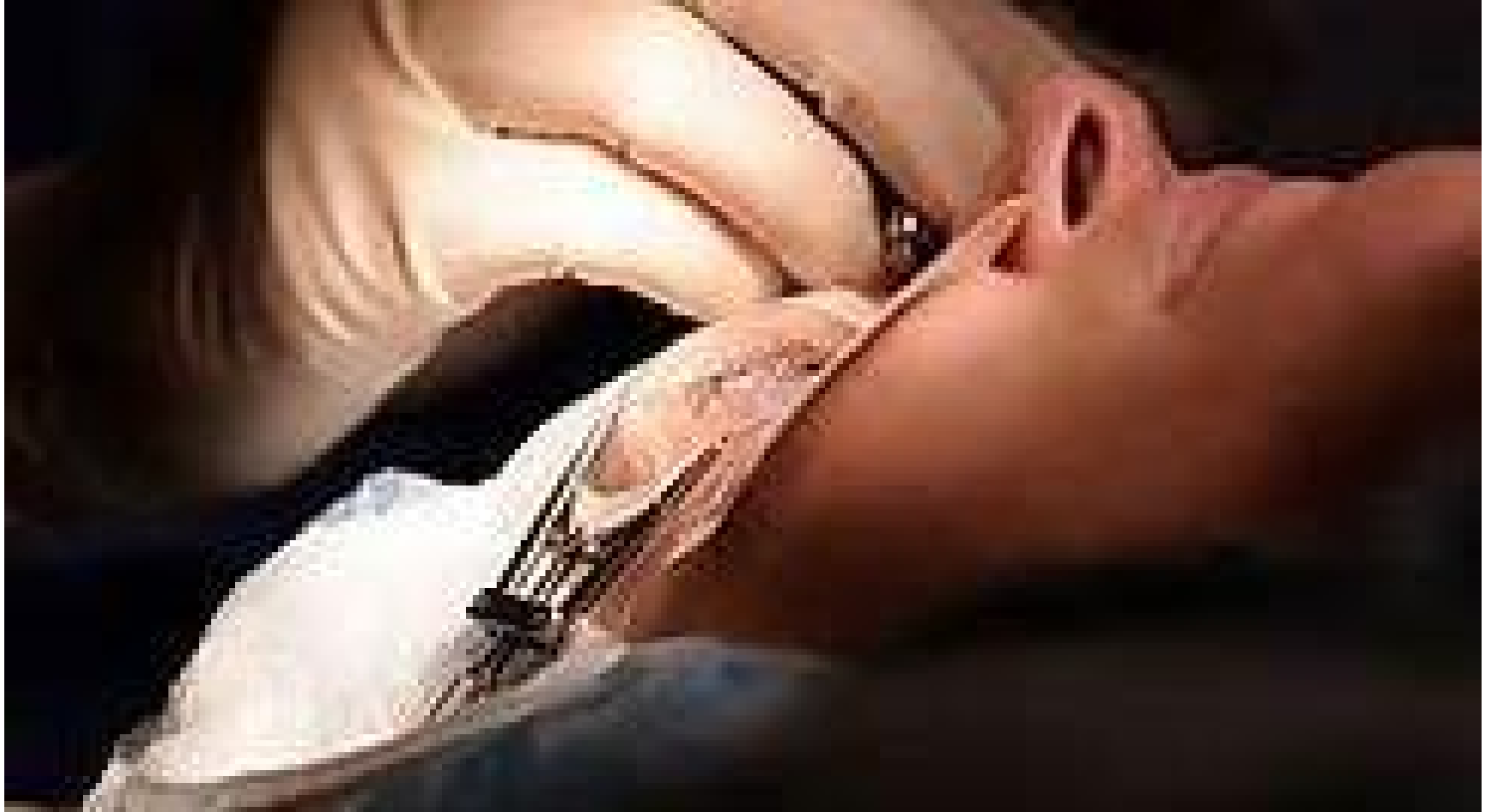# Staminali adulte



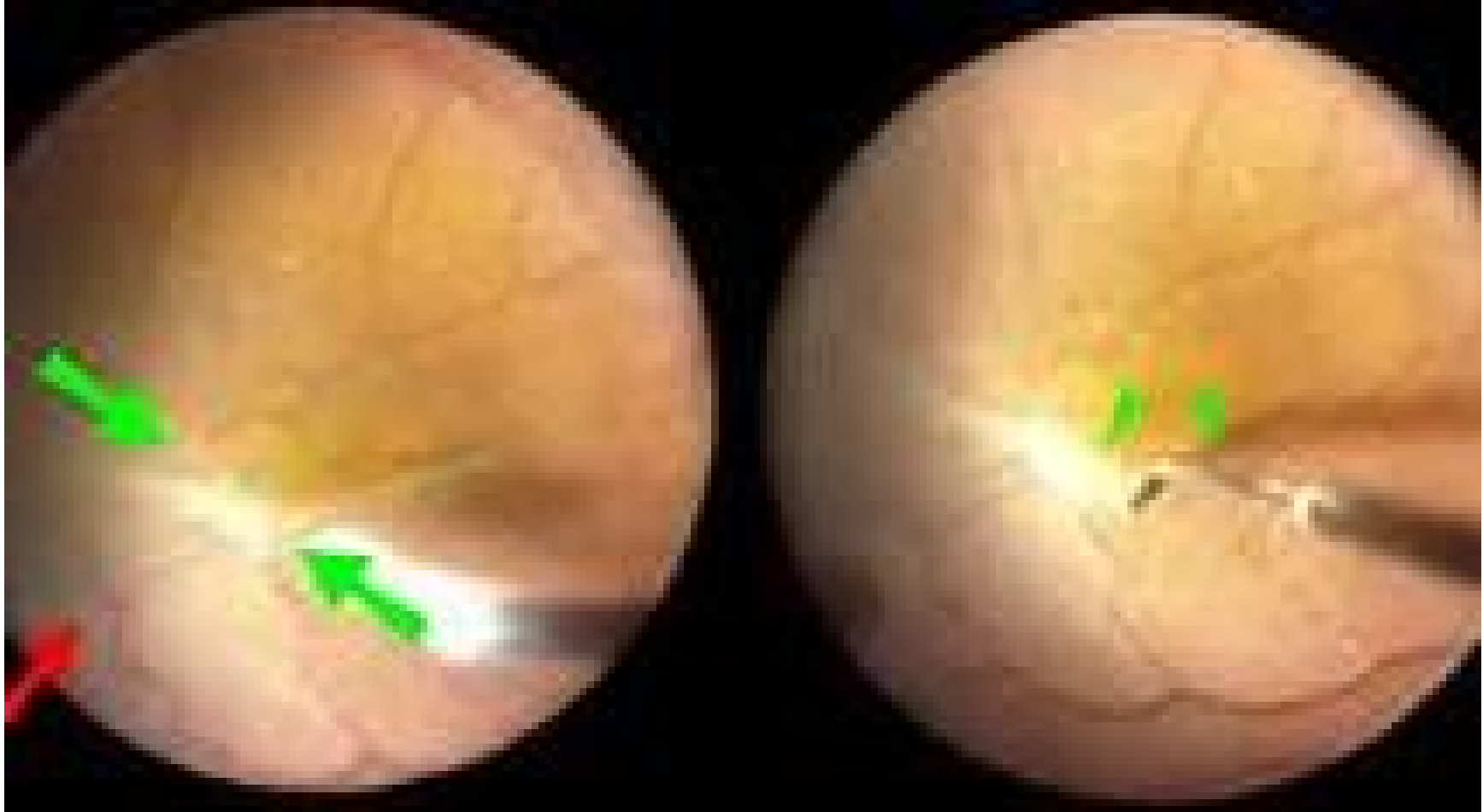
# Cellula staminale



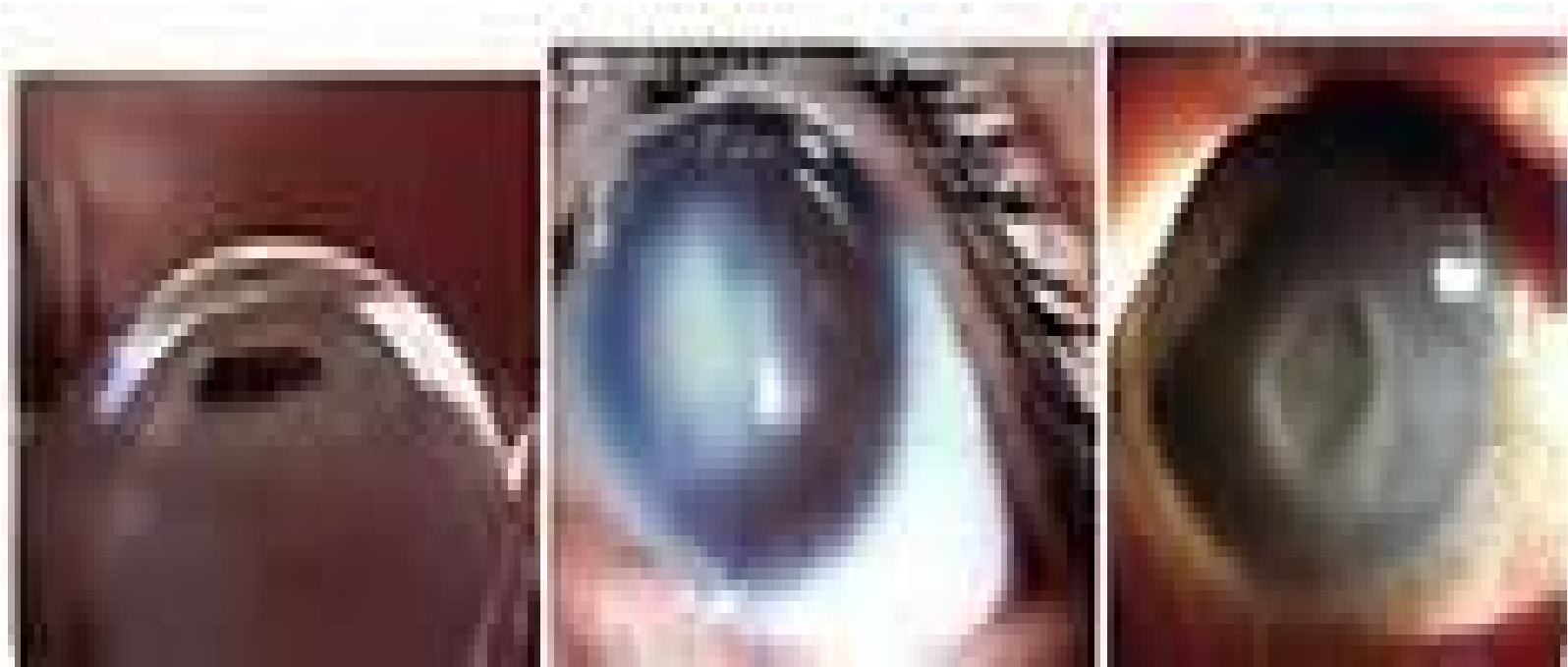
# Chirurgia maculare



# intervento sulla macula

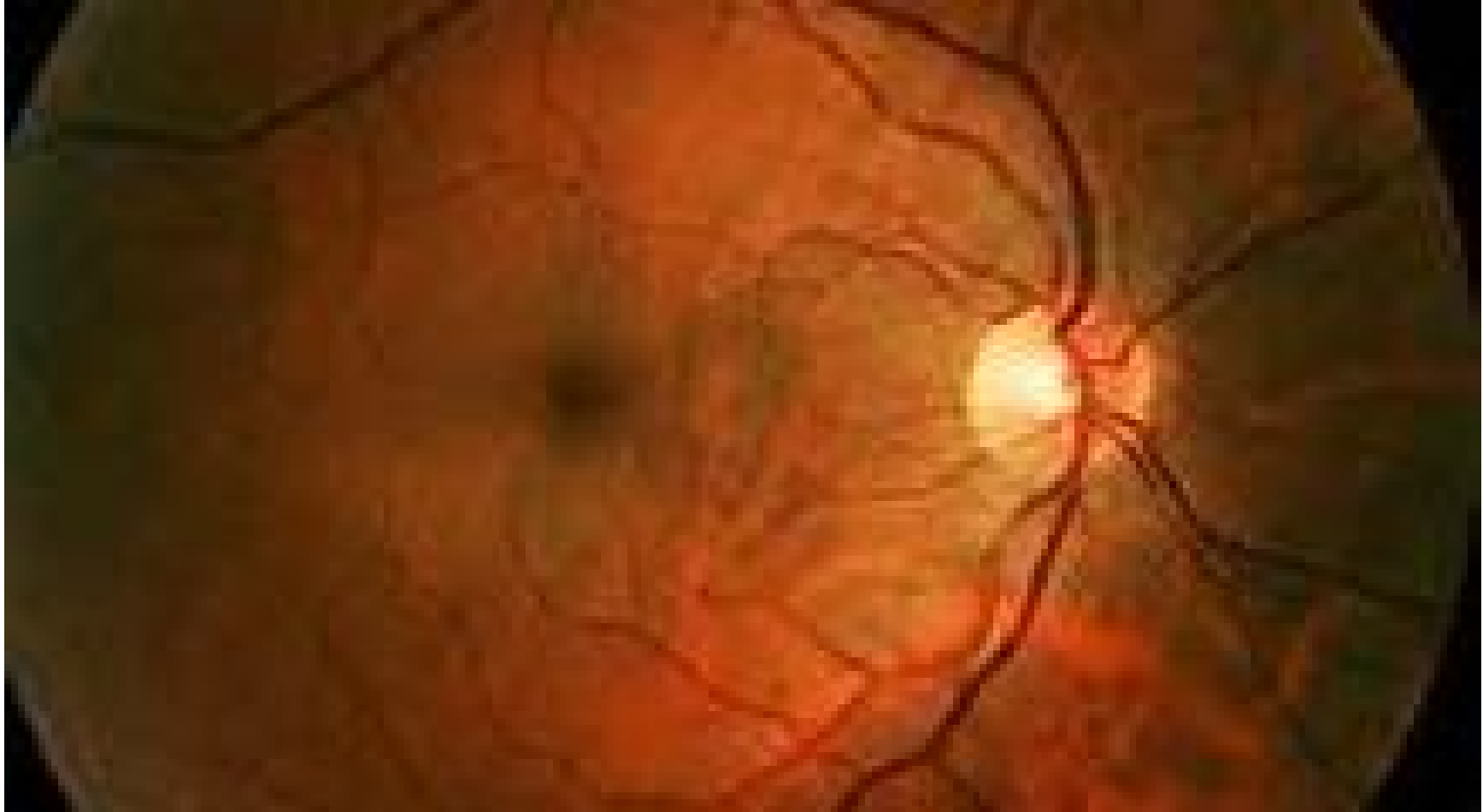


# dulte per correggere deficit limbari

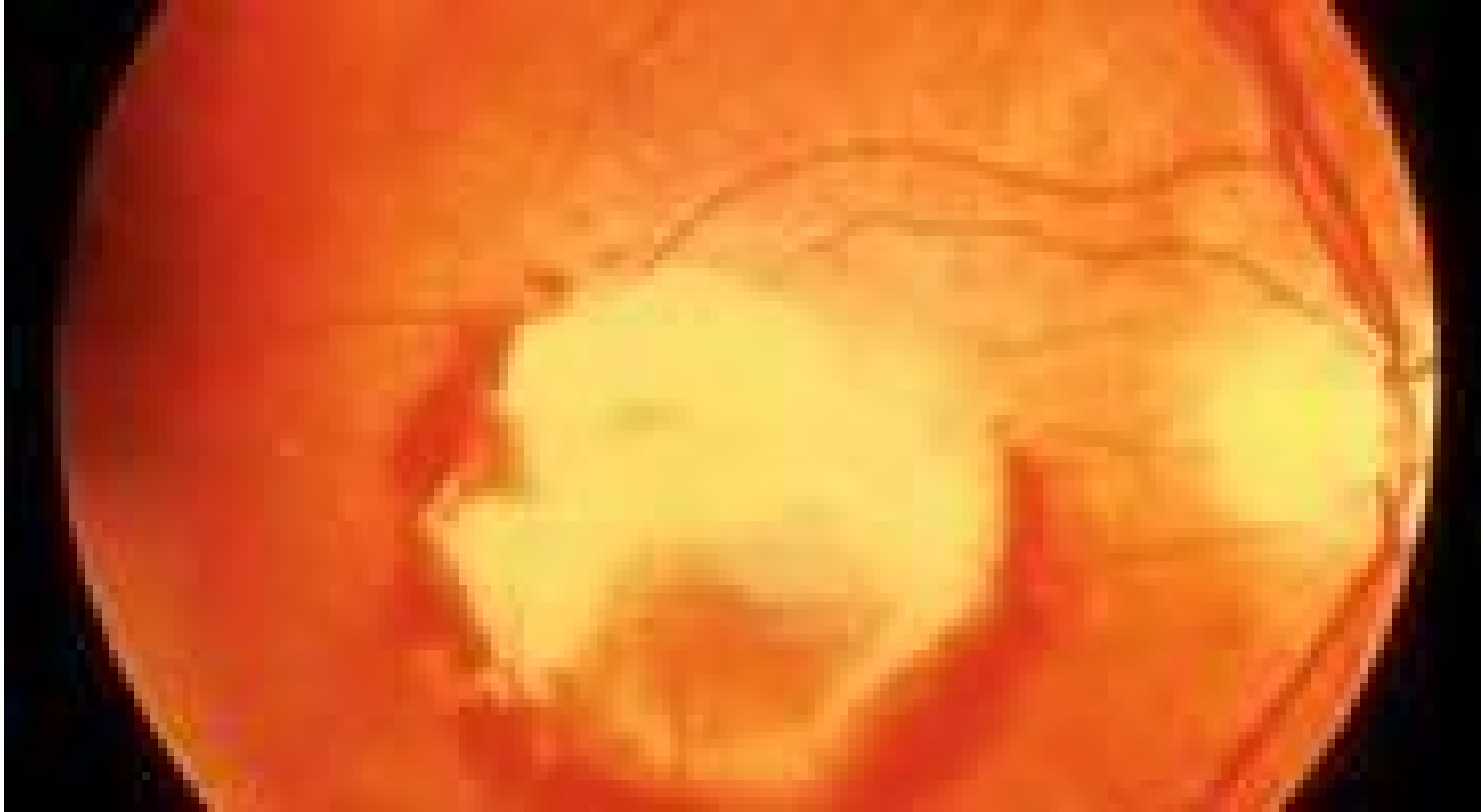



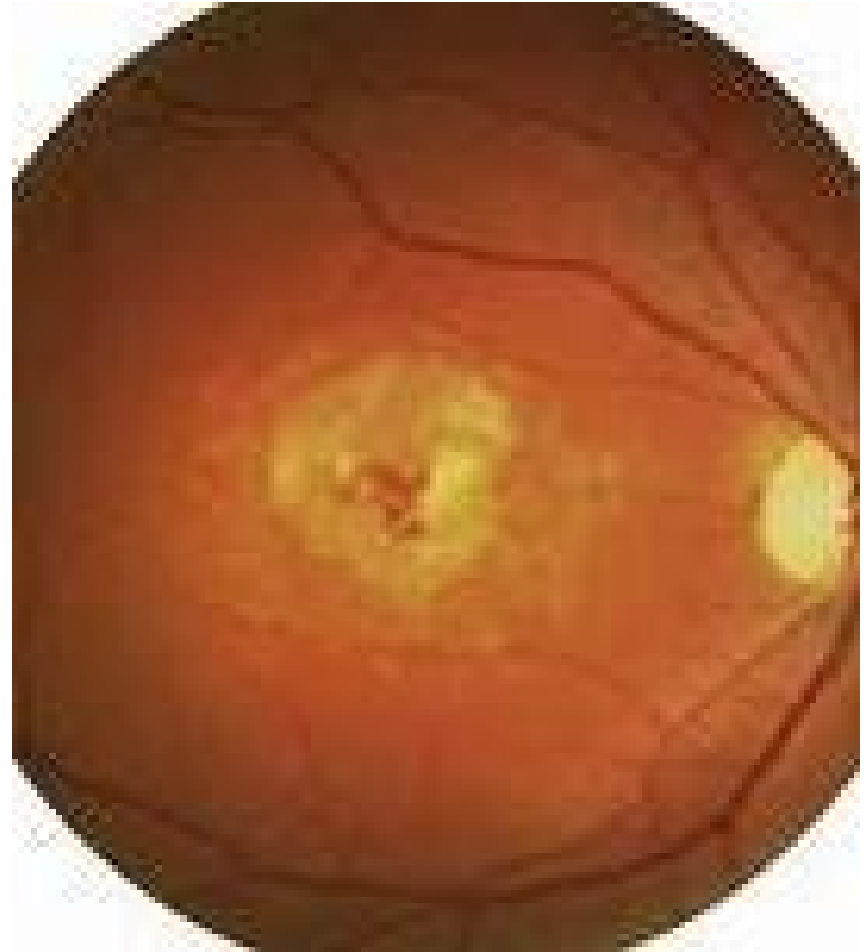
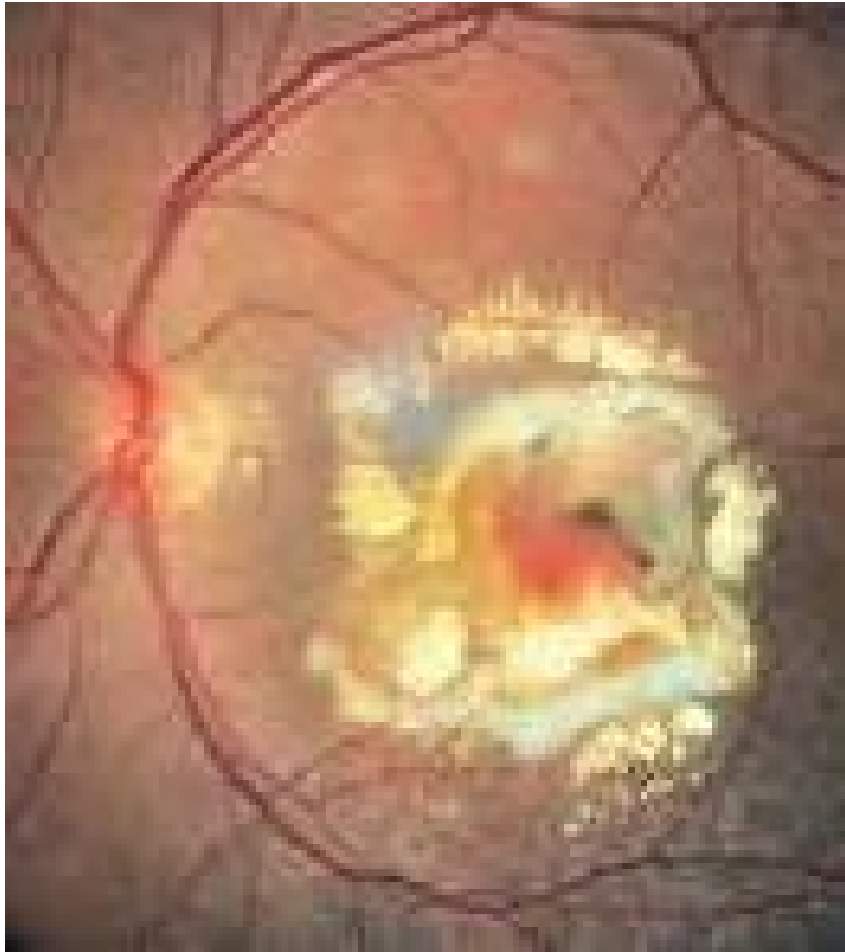
# normale fondo oculare



# Degenerazione maculare



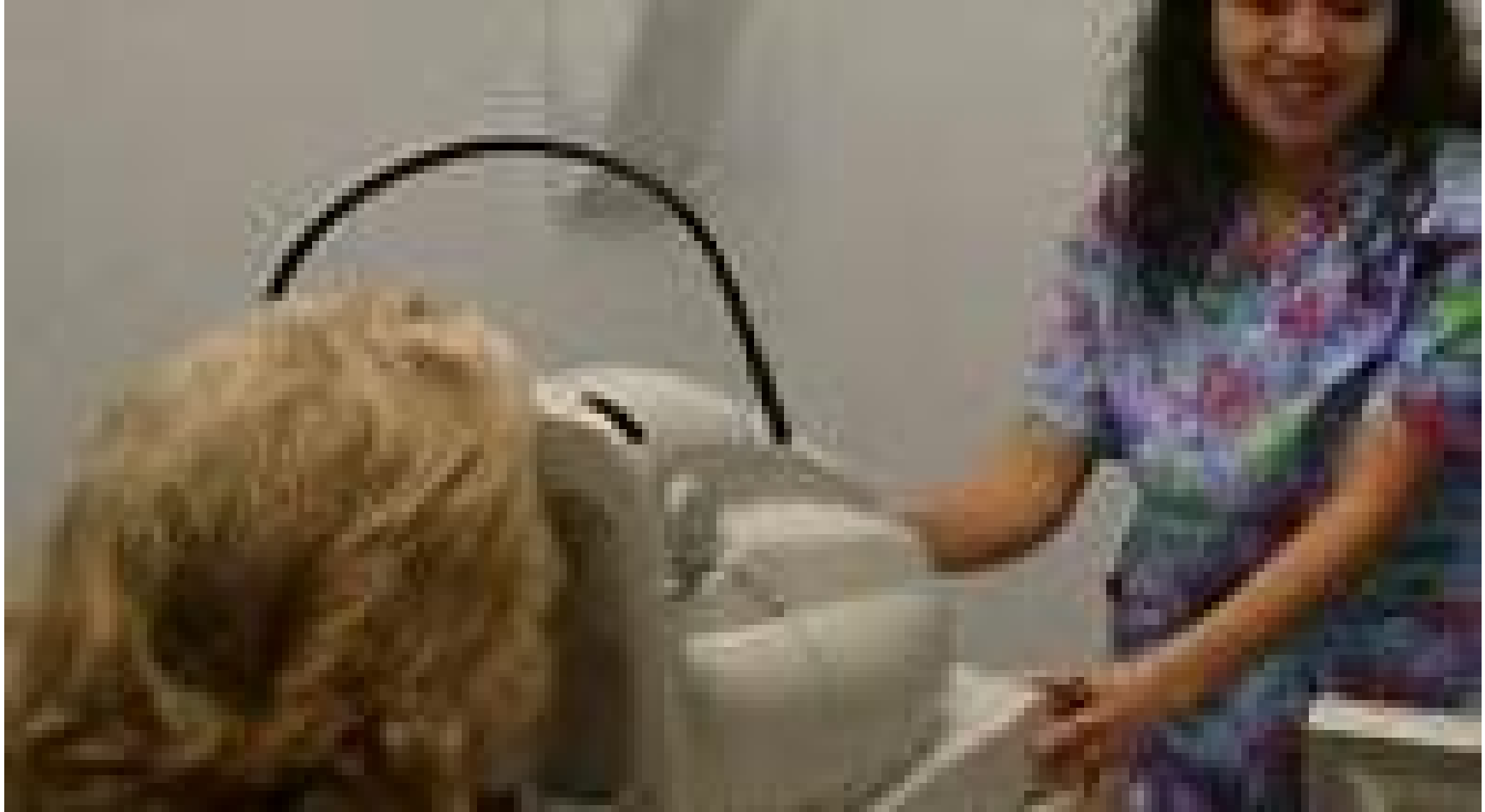# Degenerazione maculare



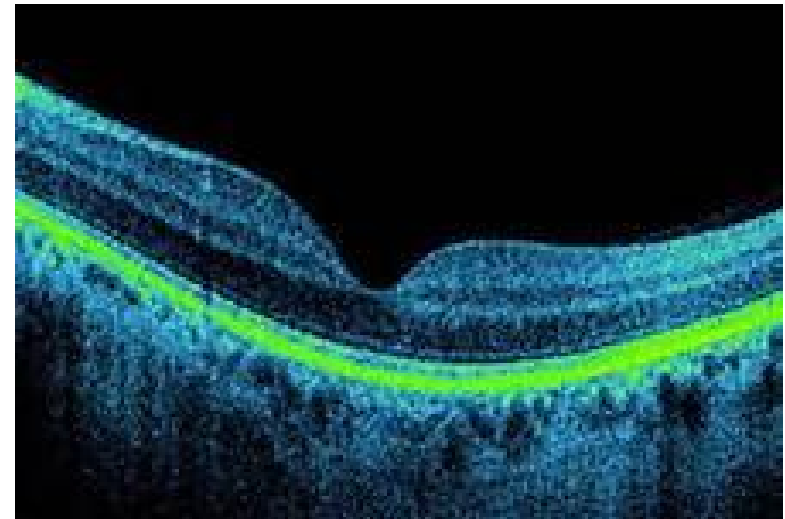
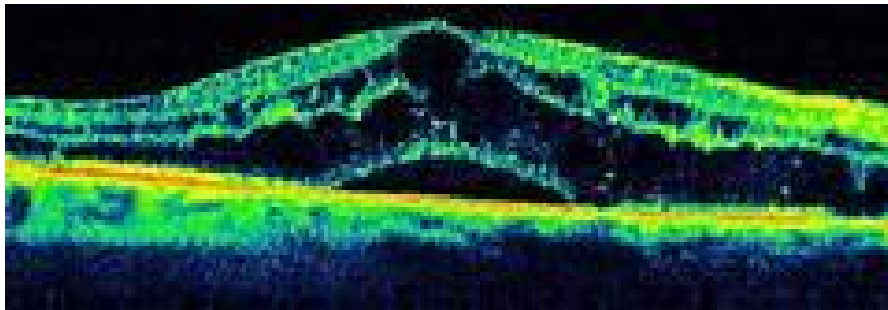
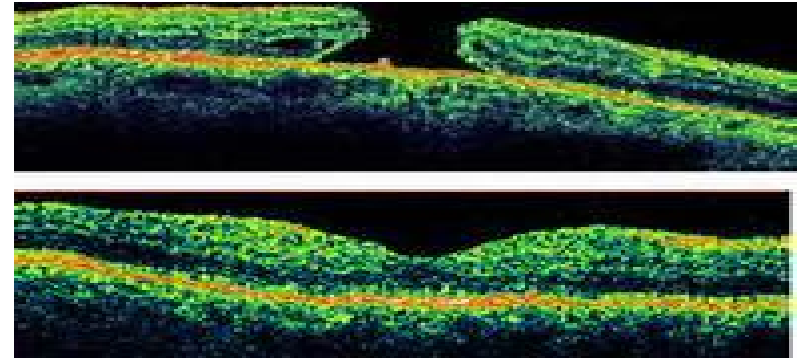
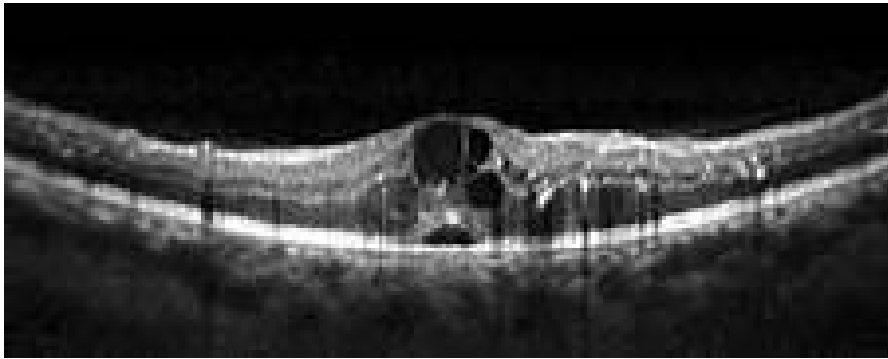
# Il danno centrale della maculopatia



# Oct maculare



# Diagnostica OCT



problema fu risolto ricreando  
una cornea artificiale. Oggi la domanda è  
rigenerare una retina distrutta

