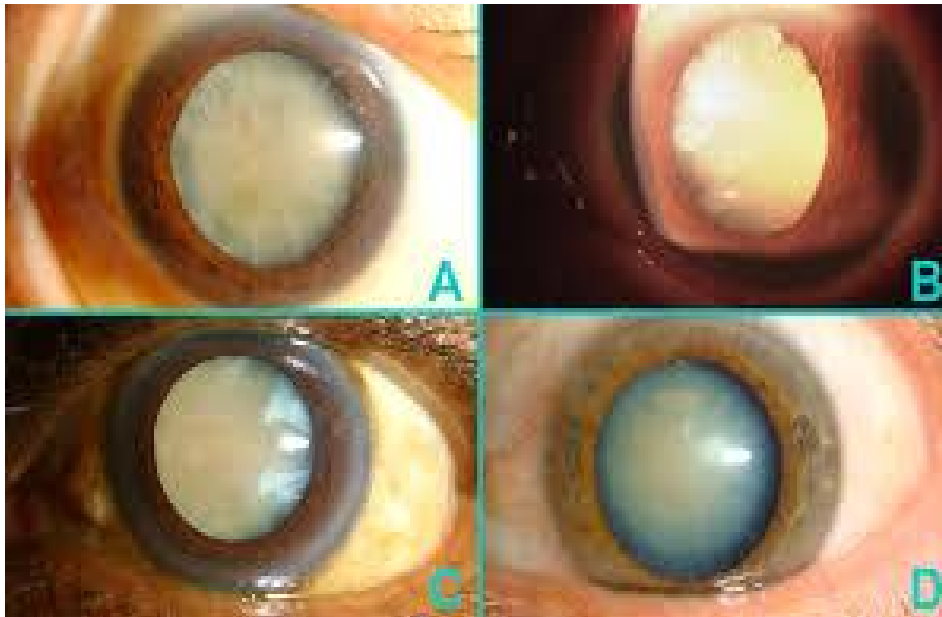


# Chirurgia oculistica

p.o. Albano laziale

22/11/2014



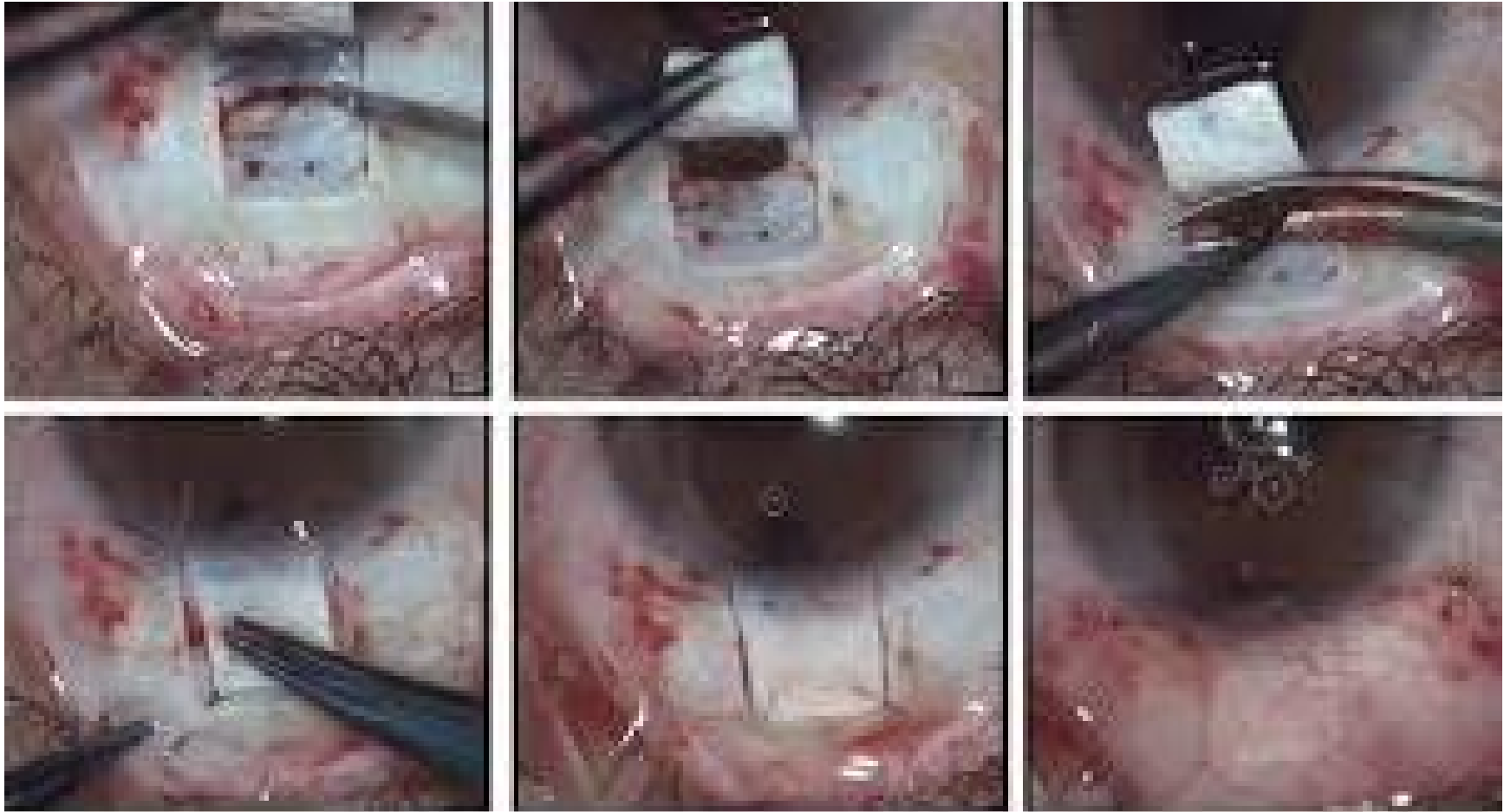# Extra capsulare



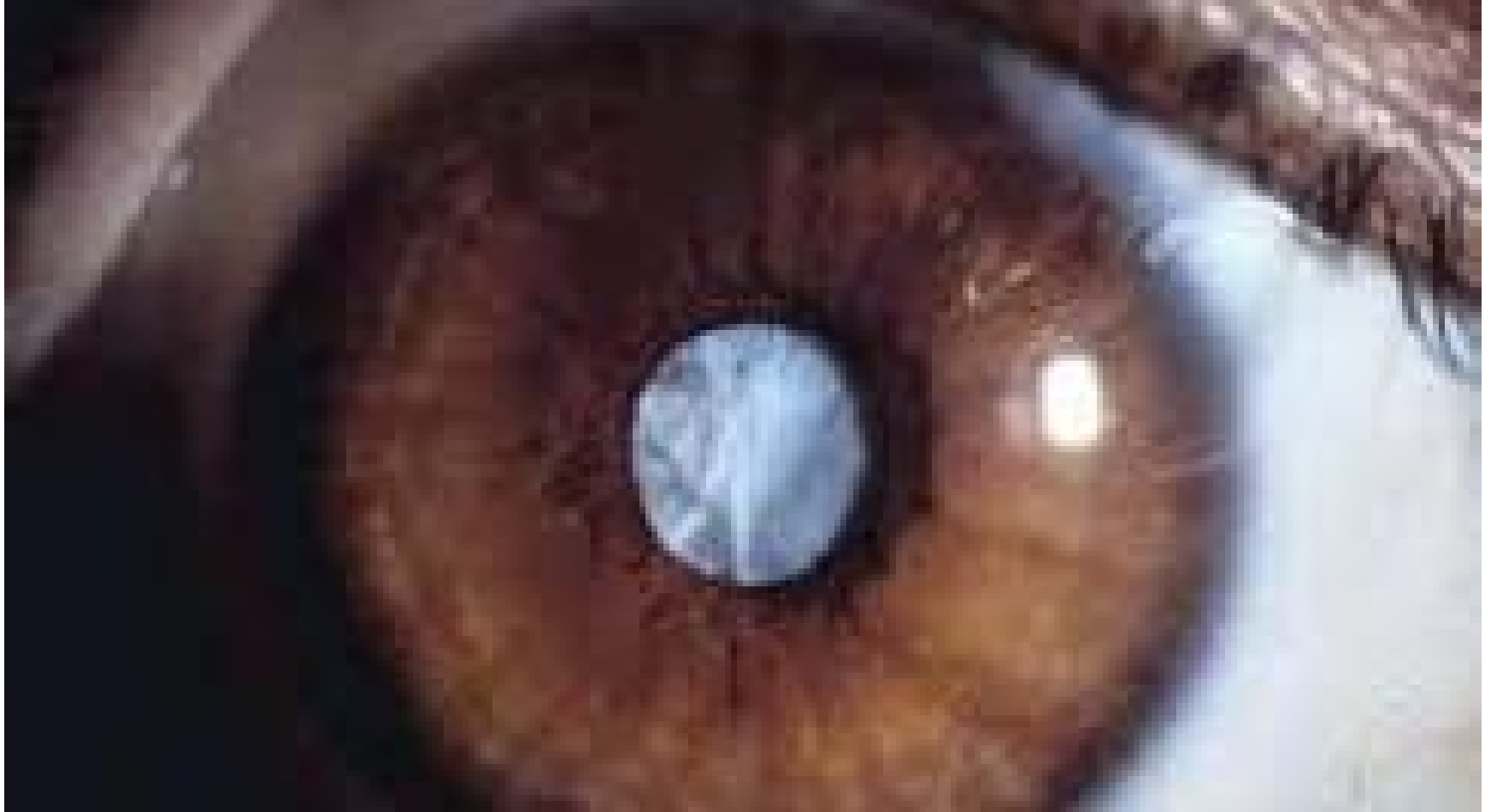# visco elastico in c.a.



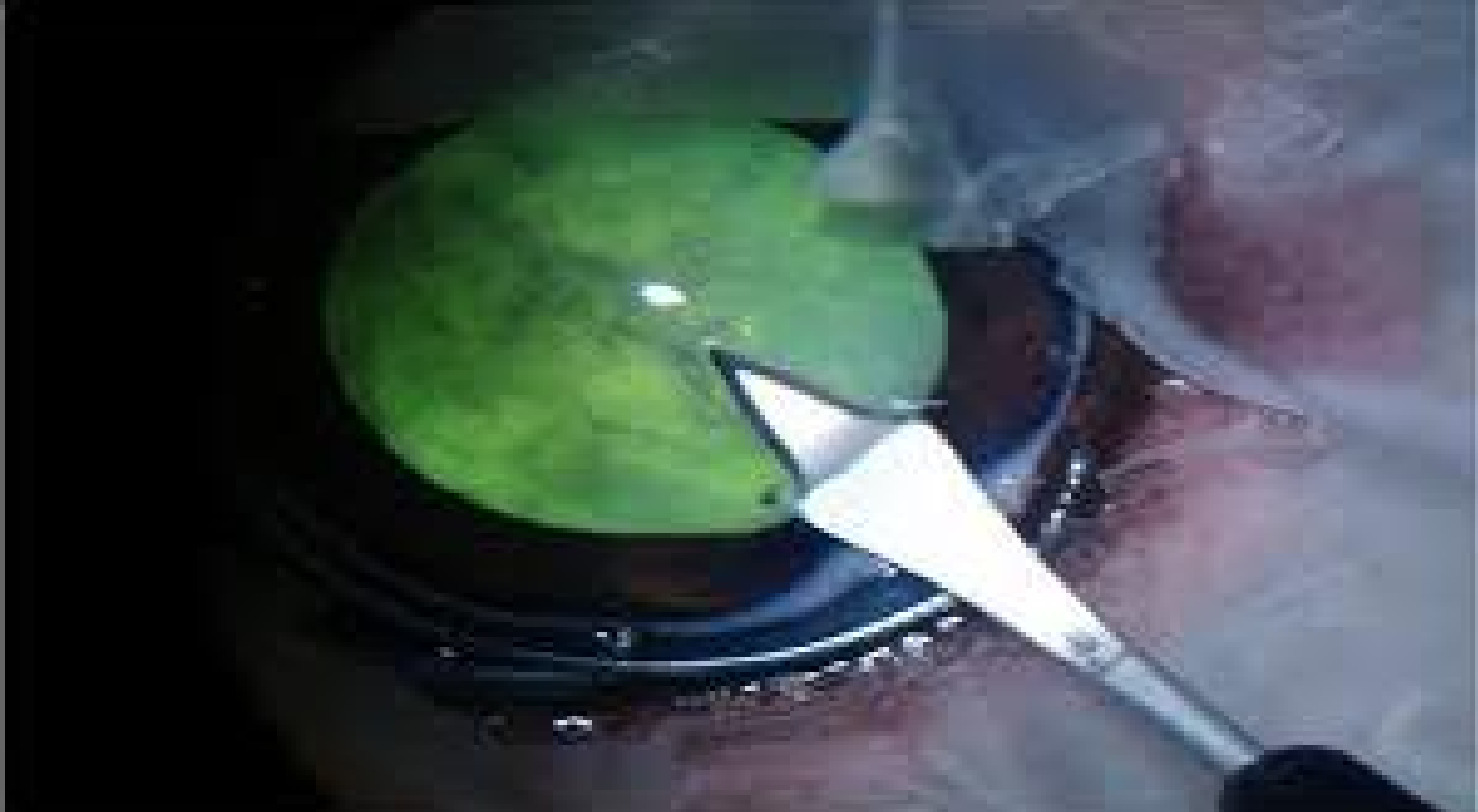# Trabeculectomy



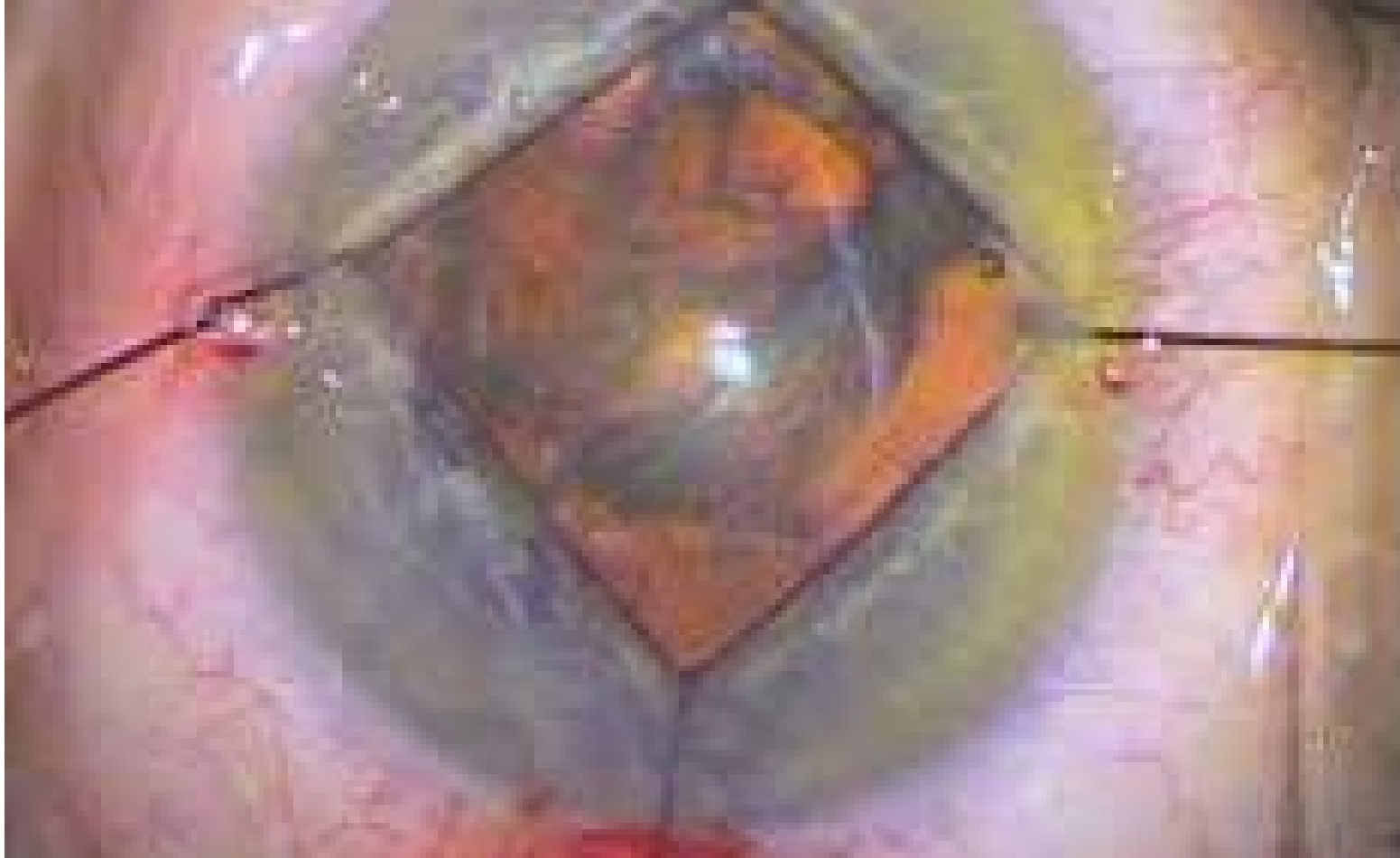# Cataratta ipermatura



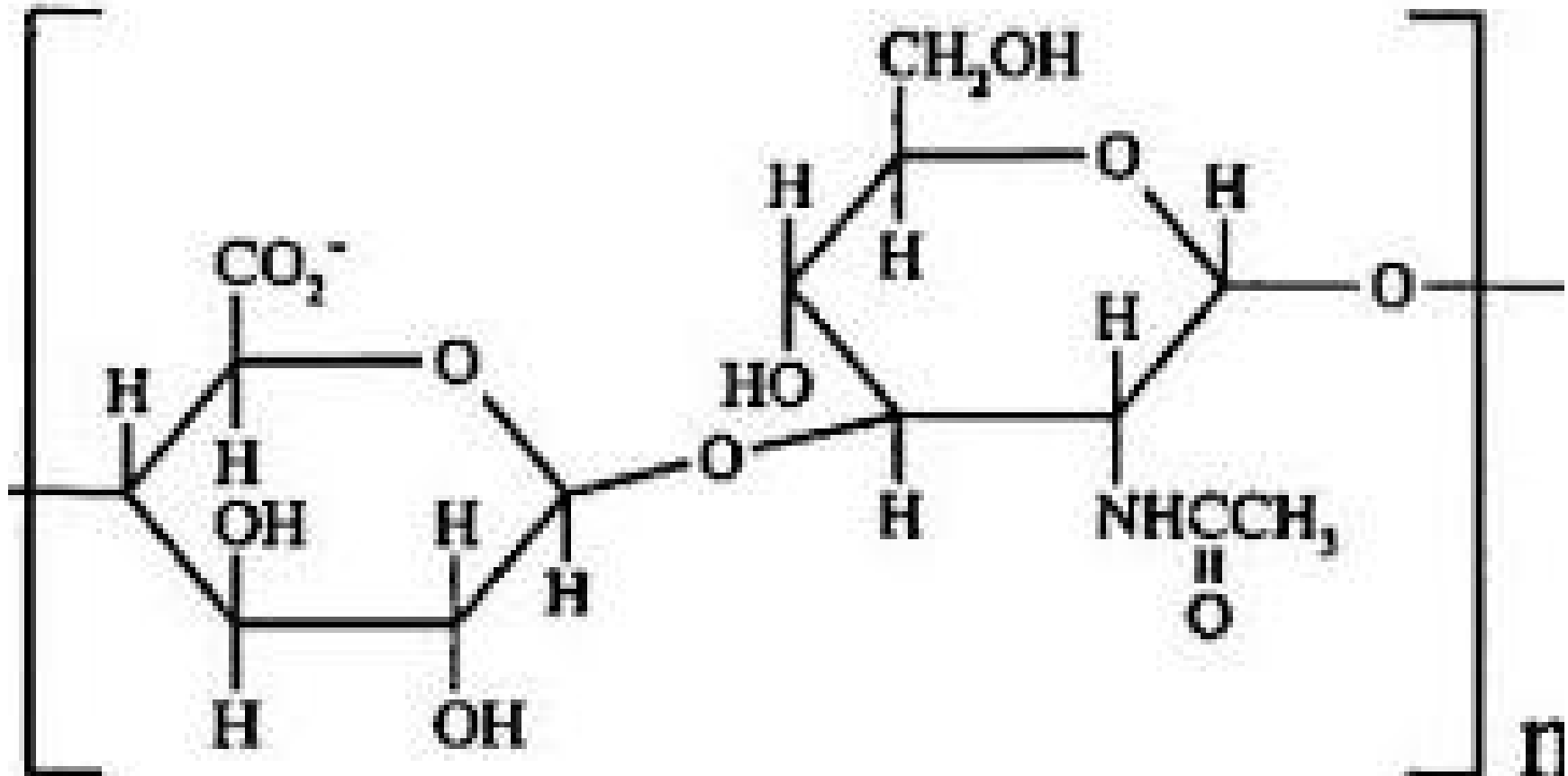
# incisione corneale



# Iris retractor



# Acido ialuronico



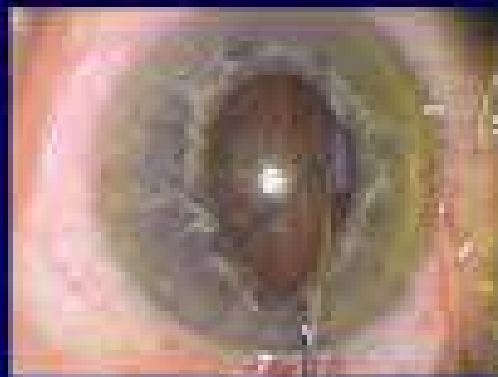


## articles

### Intraoperative floppy iris syndrome associated with tamsulosin

David F. Chang, MD, John R. Campbell, MD

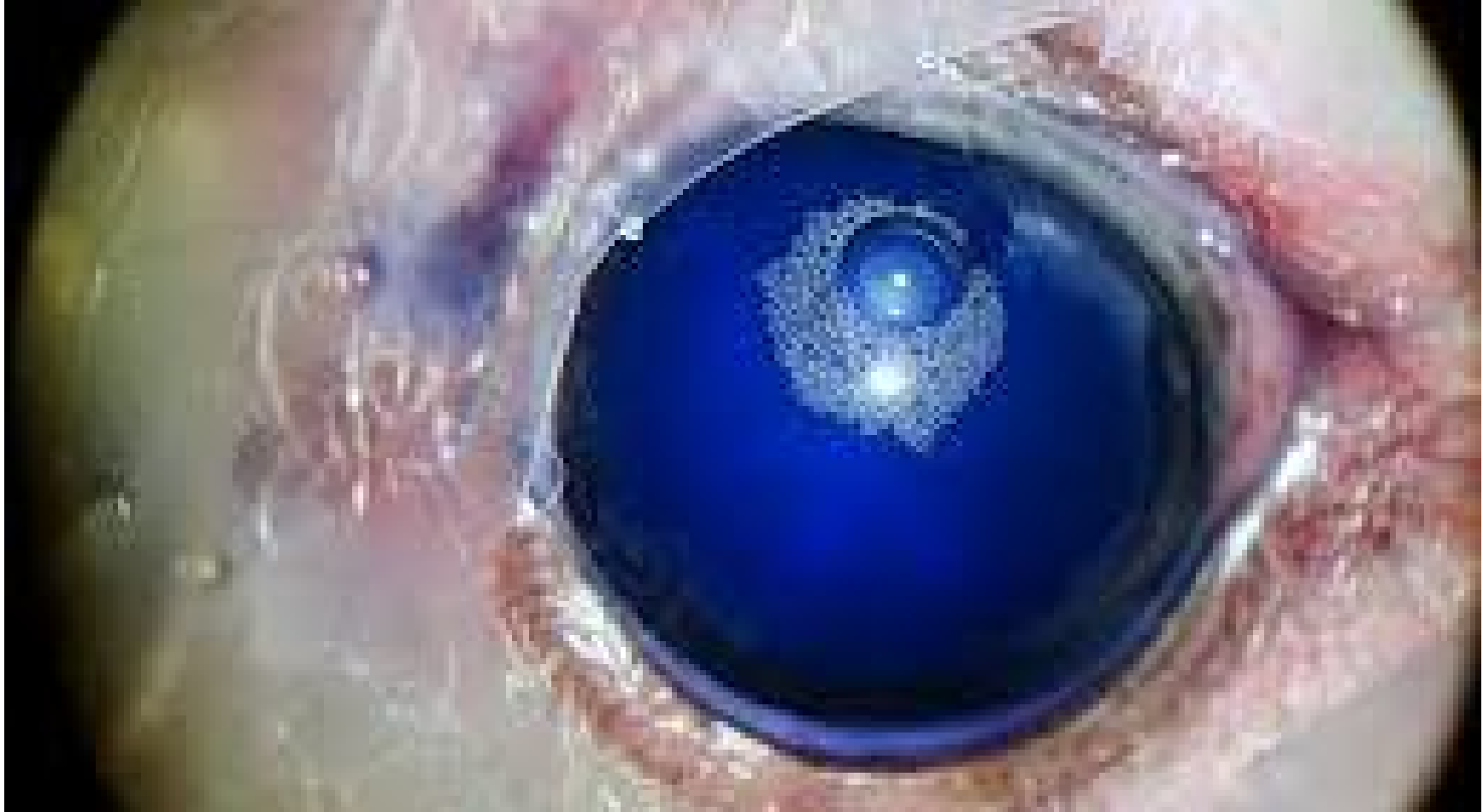*J Cataract Refract Surg* 2005; 31:664-673 © 2005 ASCRS and ESCRS



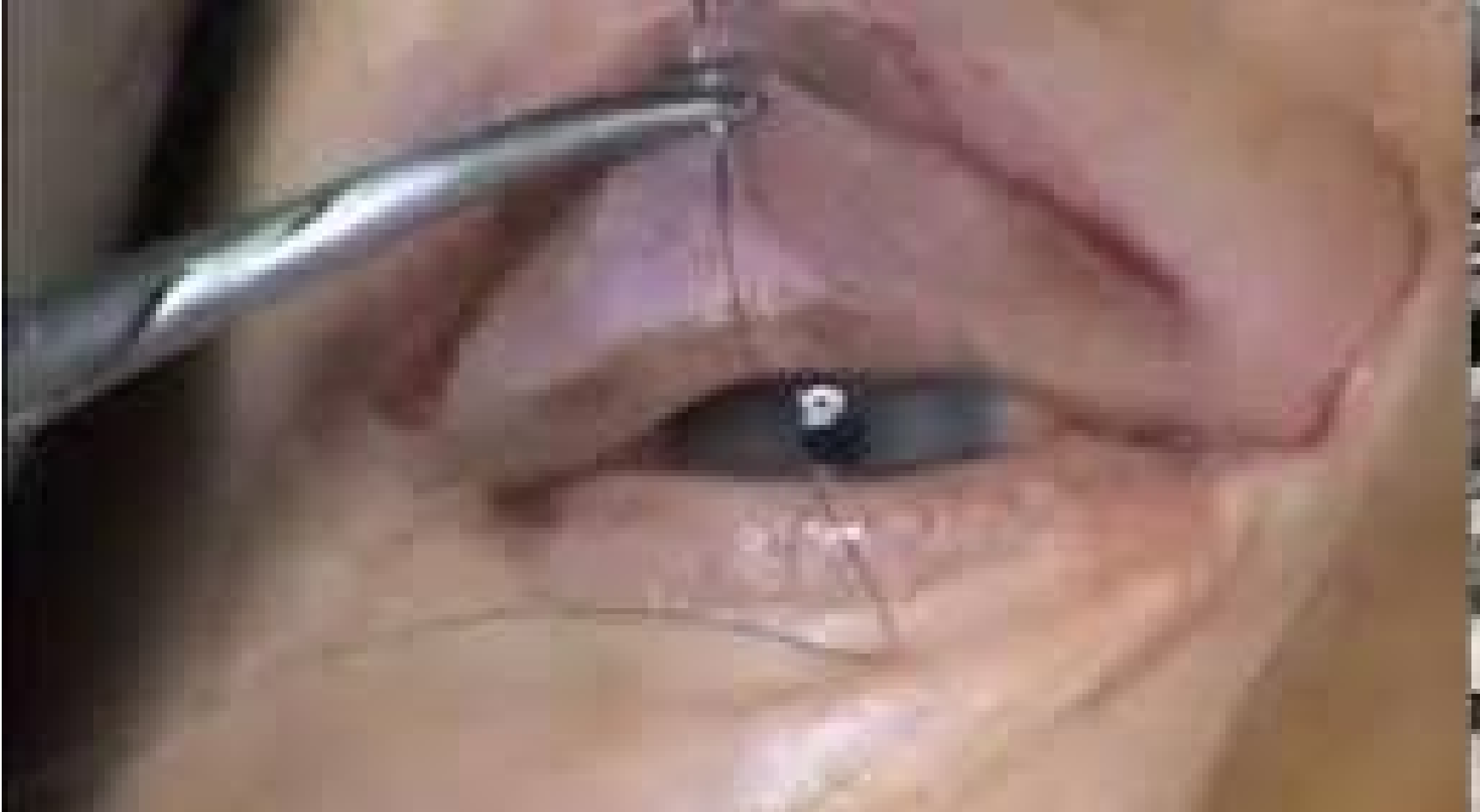# IOL



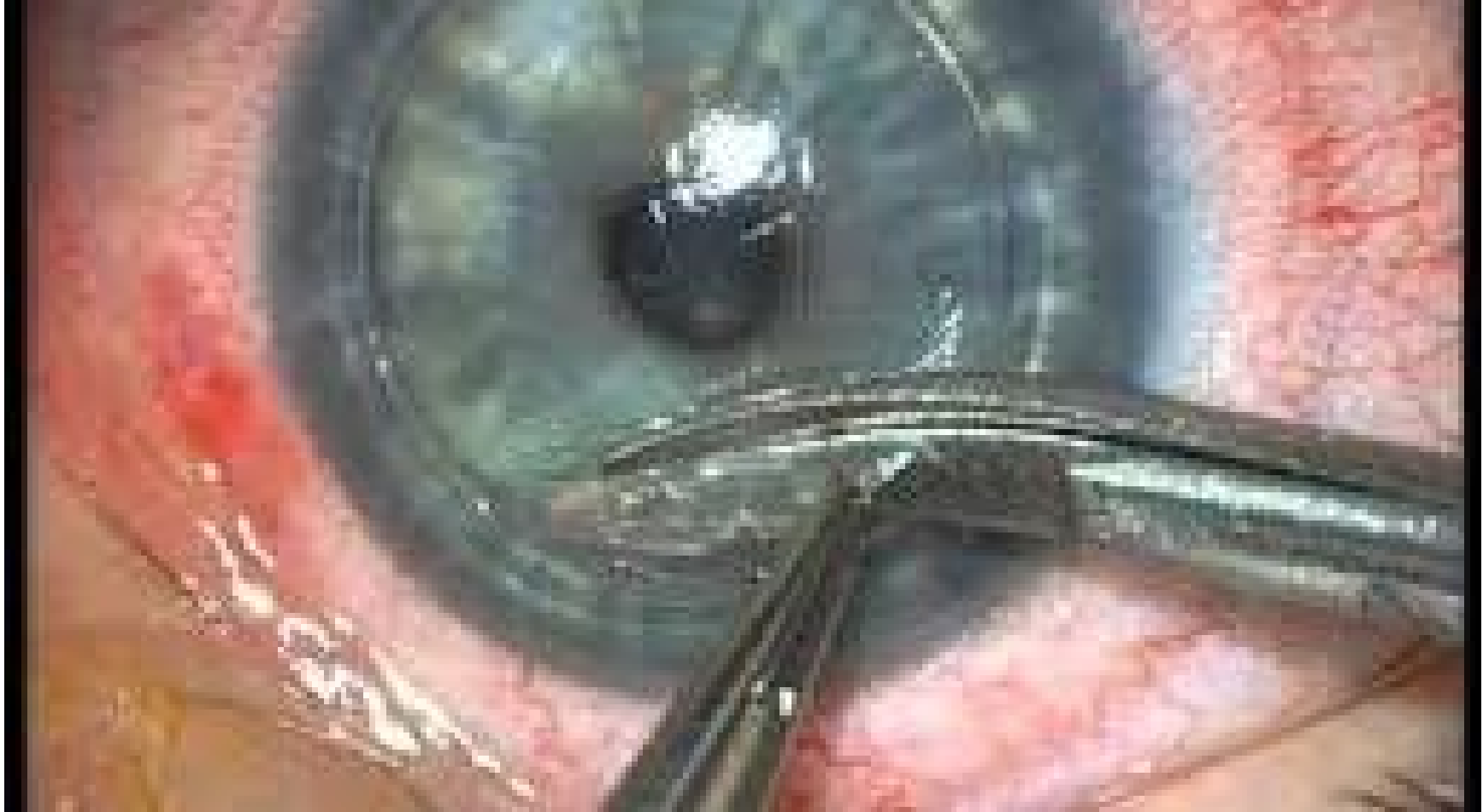# Tripan bleu



# Blefaroplastica



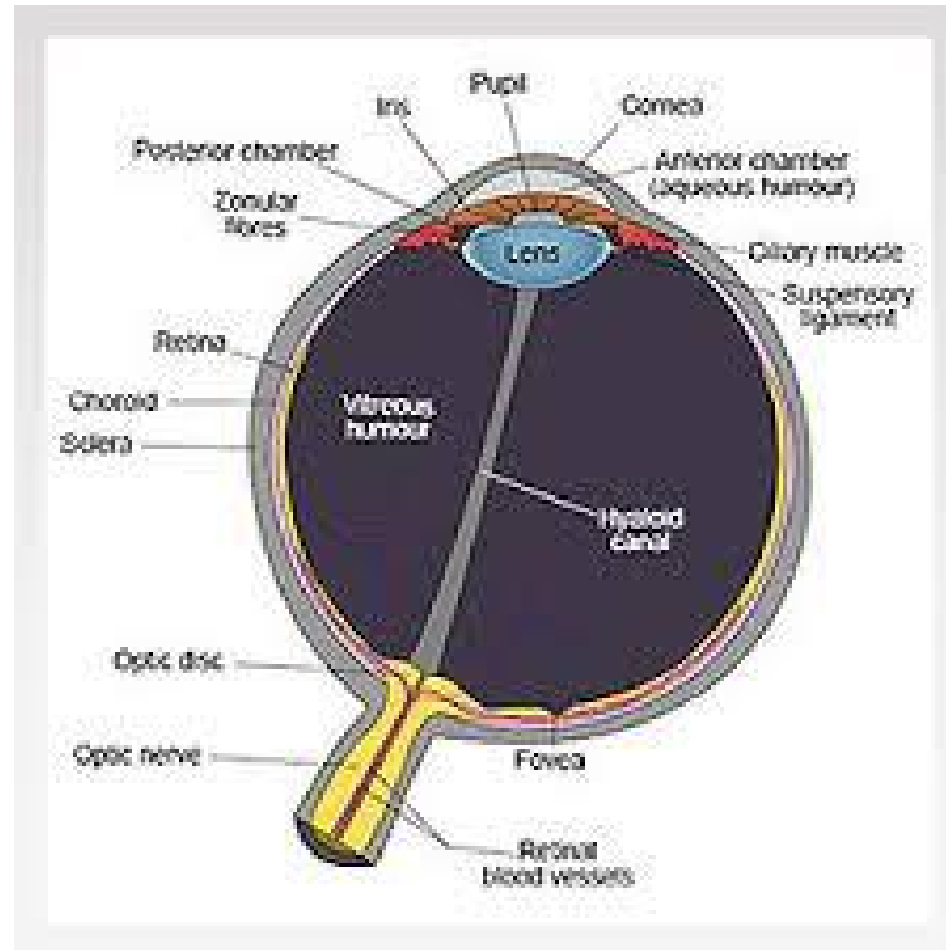
# trapianto di cornea



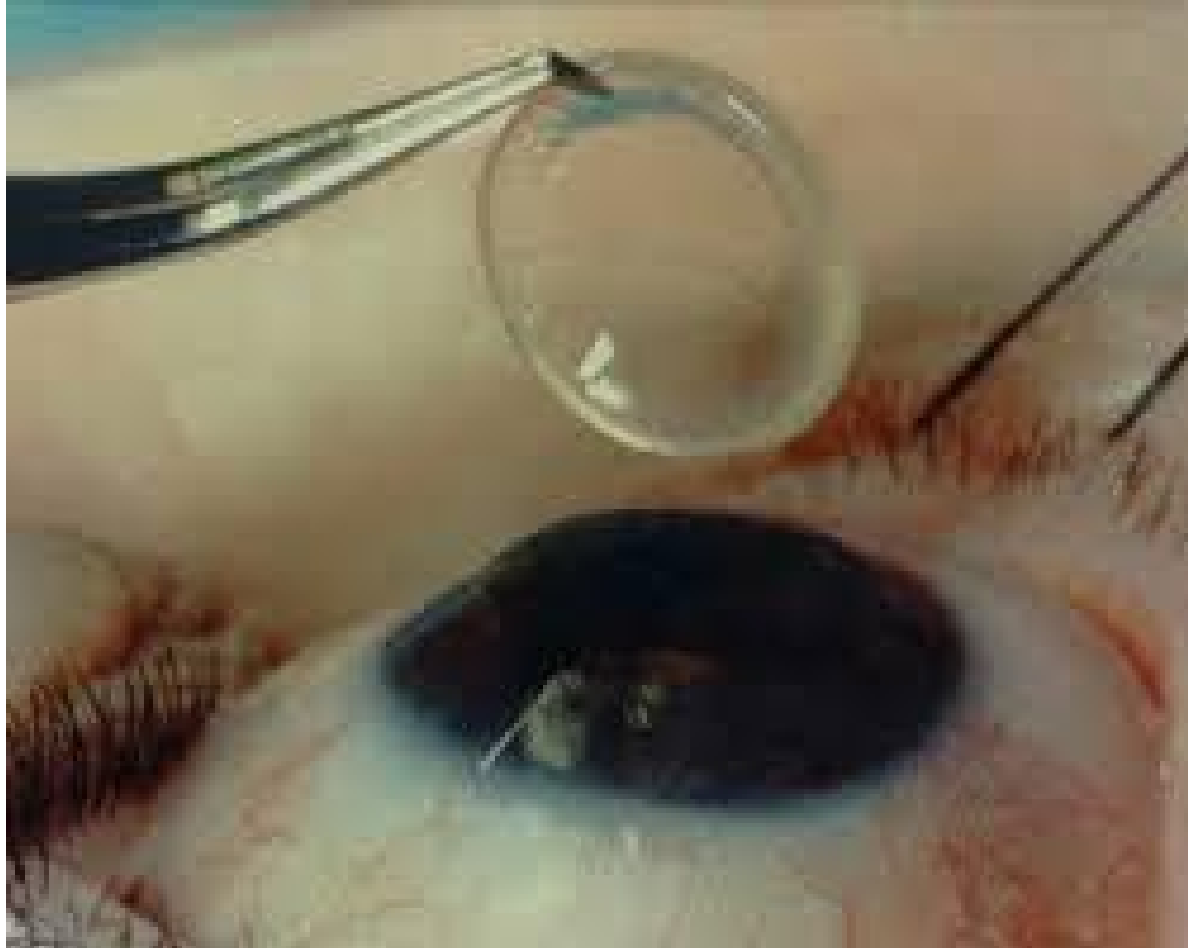
# Trapianto di cornea



# Anatomy

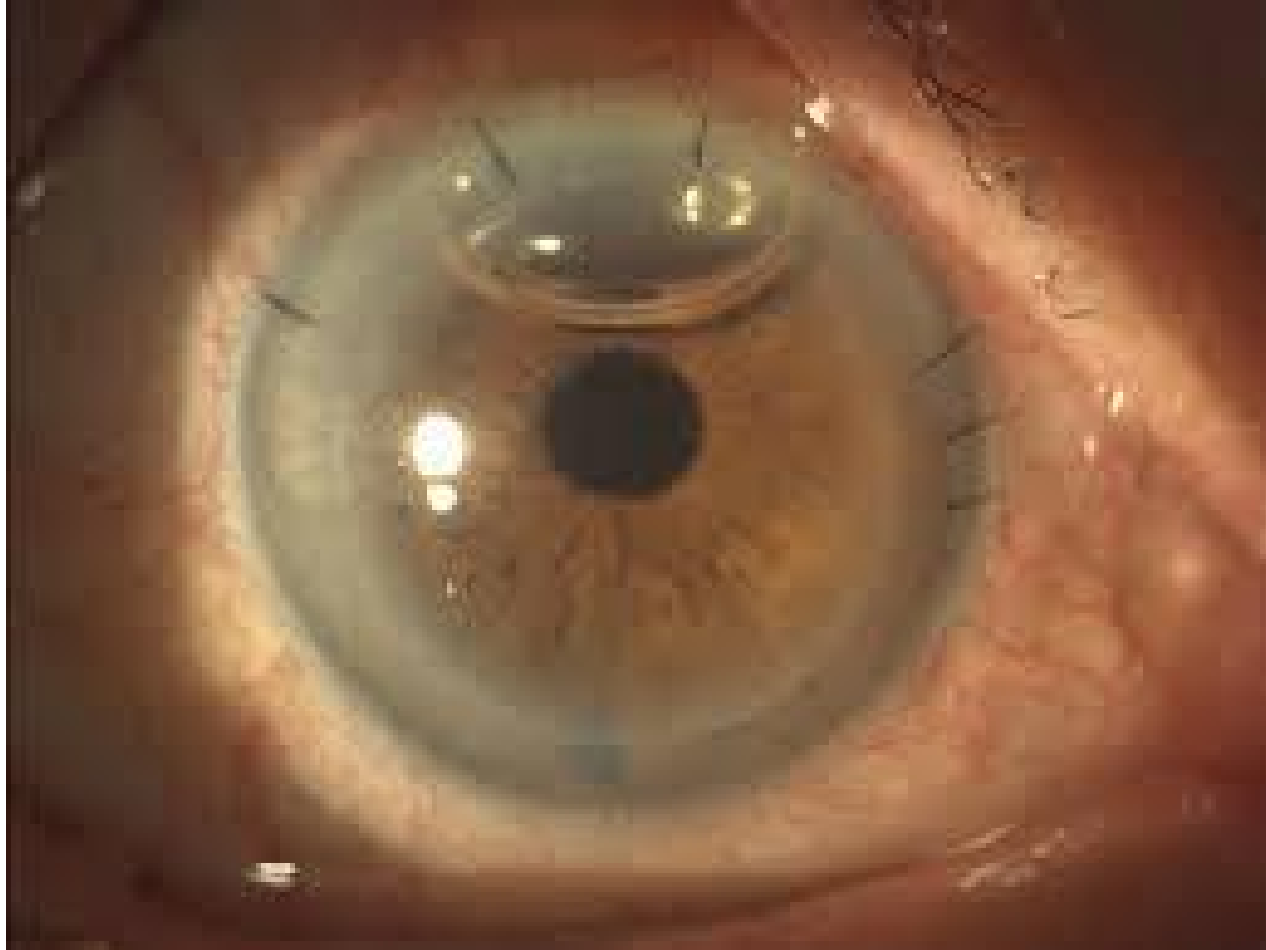


# trapianto di cornea

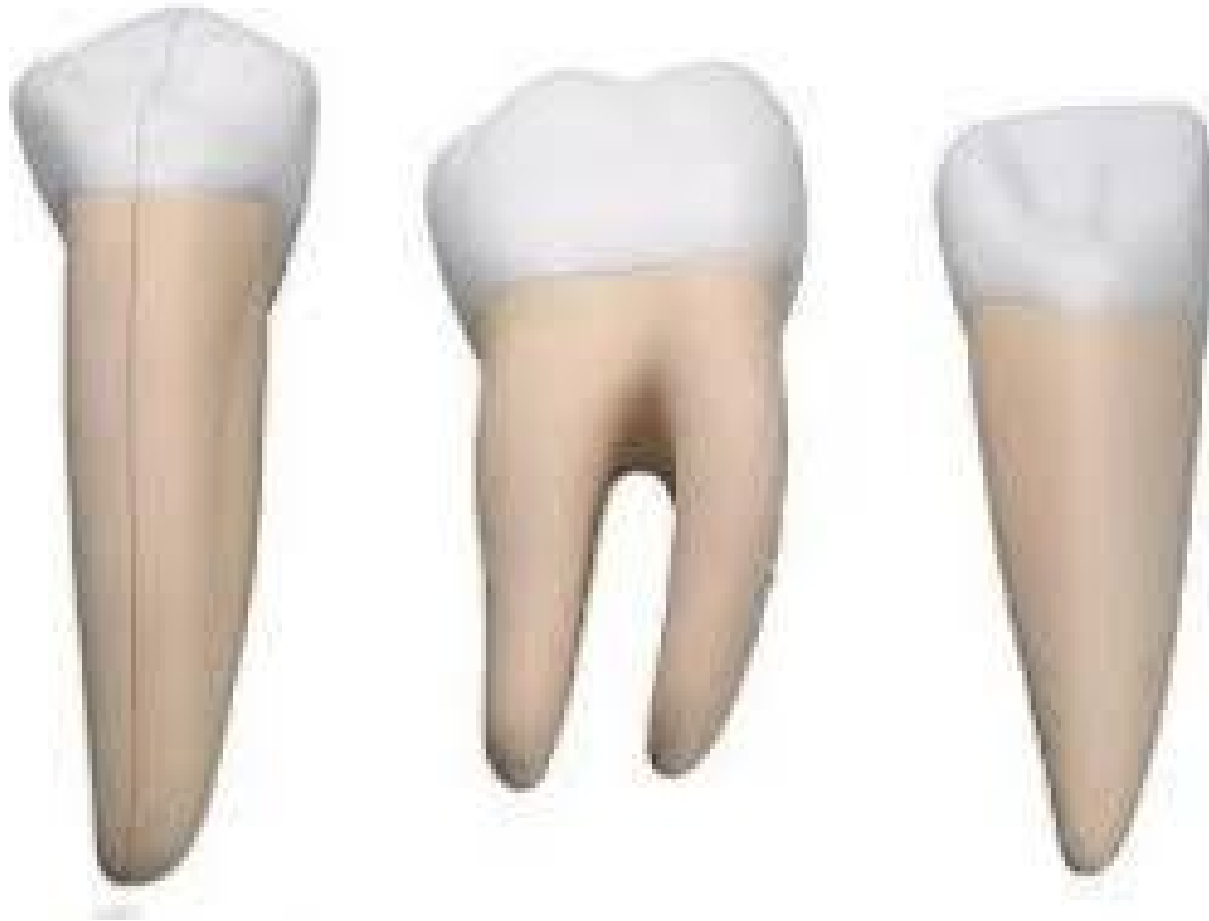



# Lacce + bolla d'aria



# Denti per OOKP




# RT Cimento plastica perforante



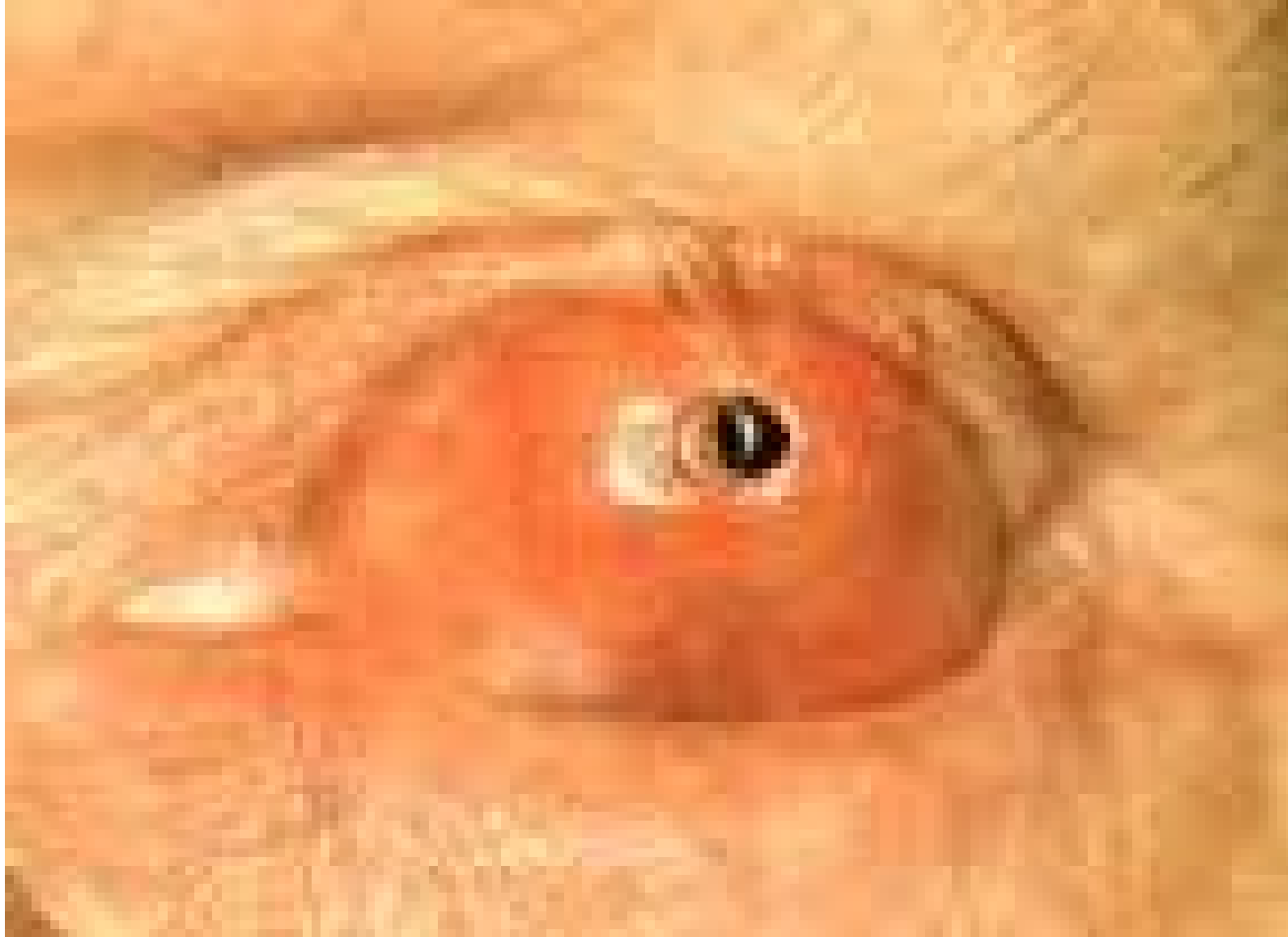

*Your complimentary  
use period has ended.  
Thank you for using  
PDF Complete.*

[Click Here to upgrade to  
Unlimited Pages and Expanded Features](#)



# OOKP





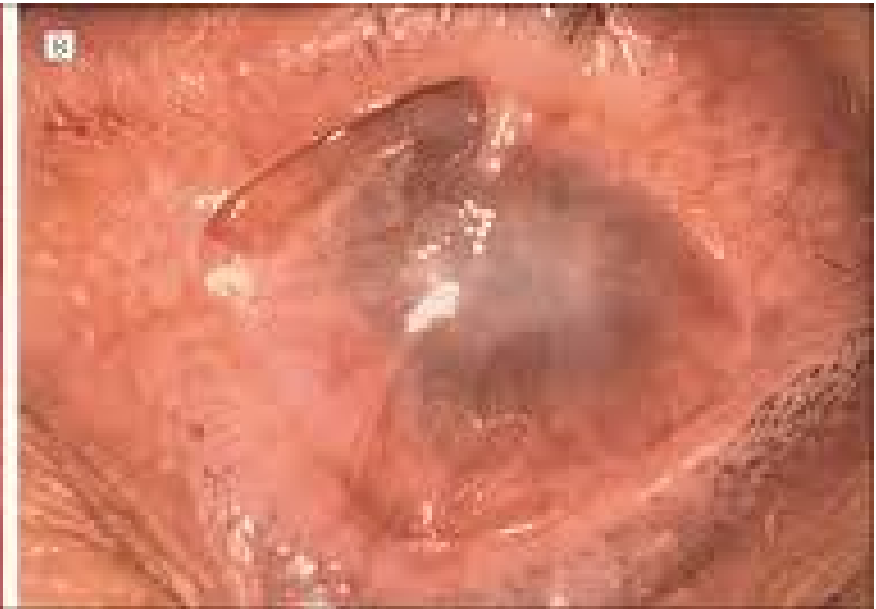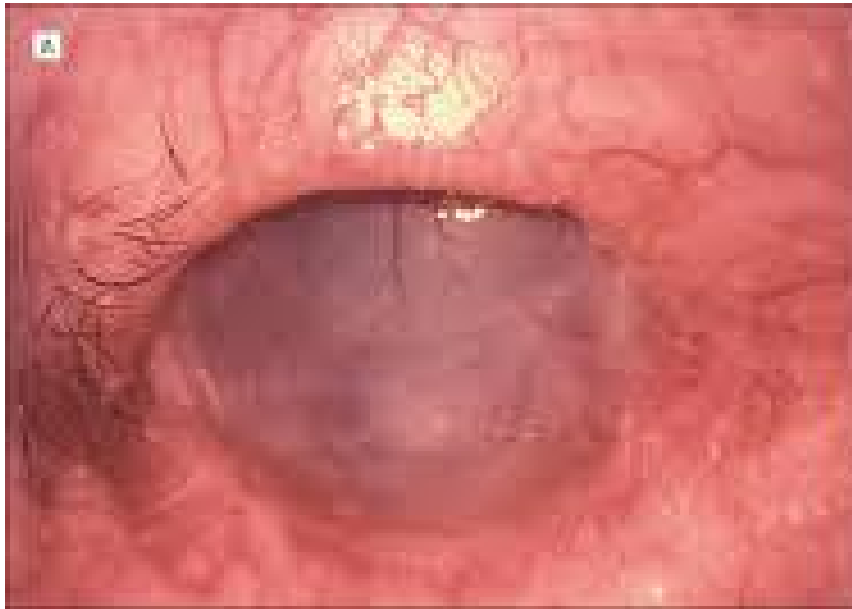*Your complimentary  
use period has ended.  
Thank you for using  
PDF Complete.*

[Click Here to upgrade to  
Unlimited Pages and Expanded Features](#)

# OOKP



# emfigo cicatriziale



# Ospedale San Camillo Forlanini

