



*Your complimentary
use period has ended.
Thank you for using
PDF Complete.*

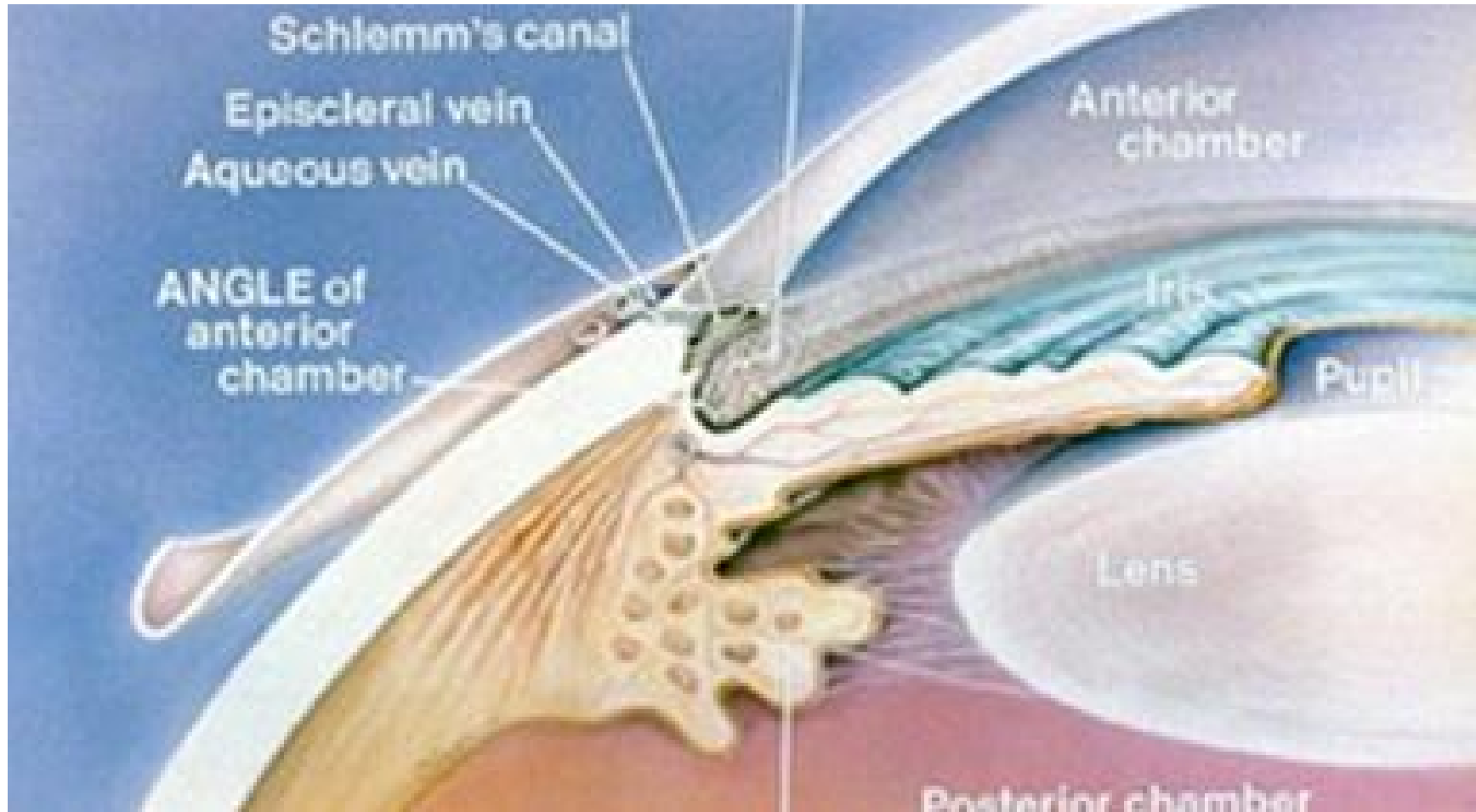
[Click Here to upgrade to
Unlimited Pages and Expanded Features](#)

Il prelievo sclero-corneale e il trapianto di cornea

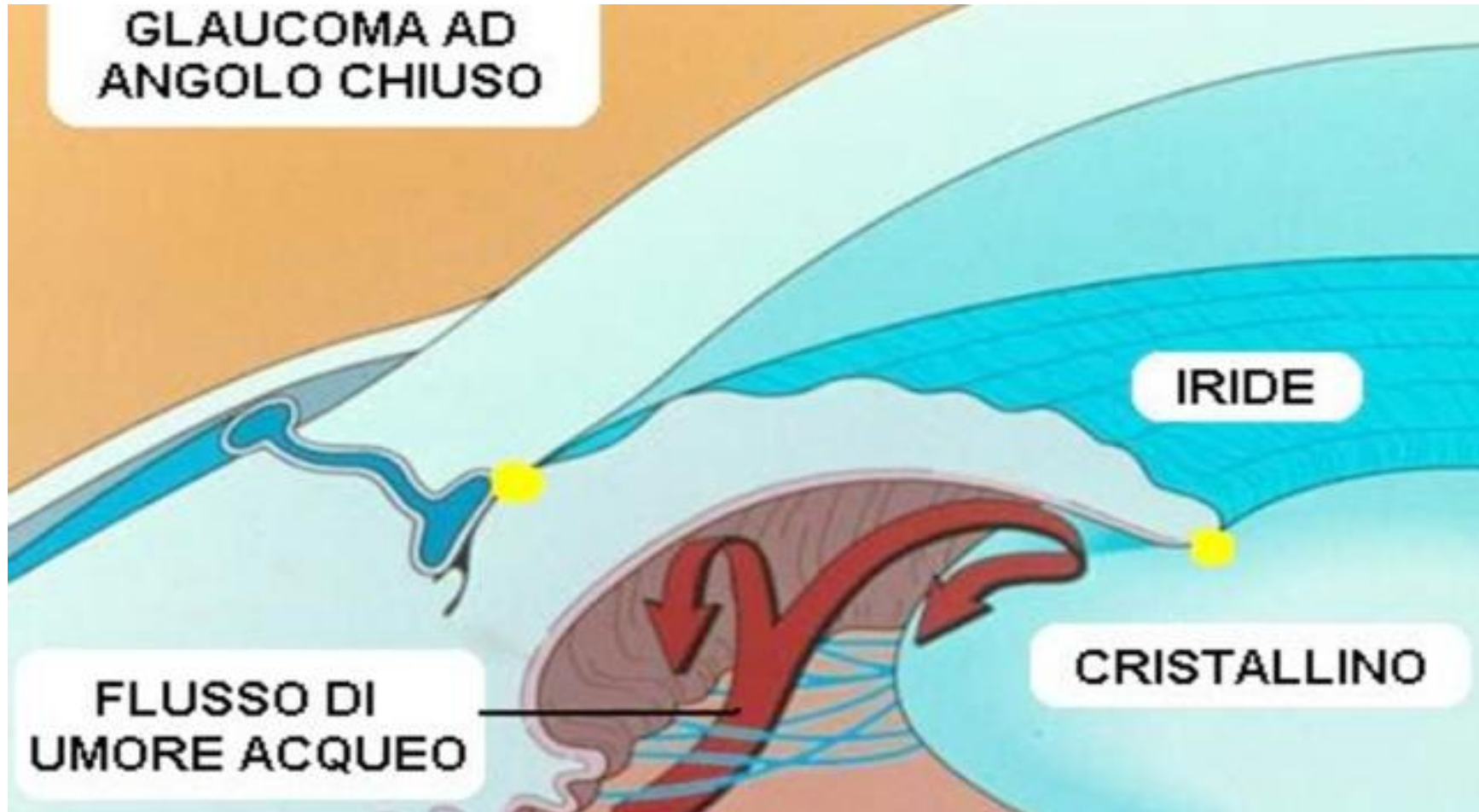
Un impegno a servire l'uomo

Dott. Franco Arrigoni
Direttore U.O.S. chirurgia oculistica
P.O. Genzano di Roma
ASL RMH

Anatomia oculare particolare

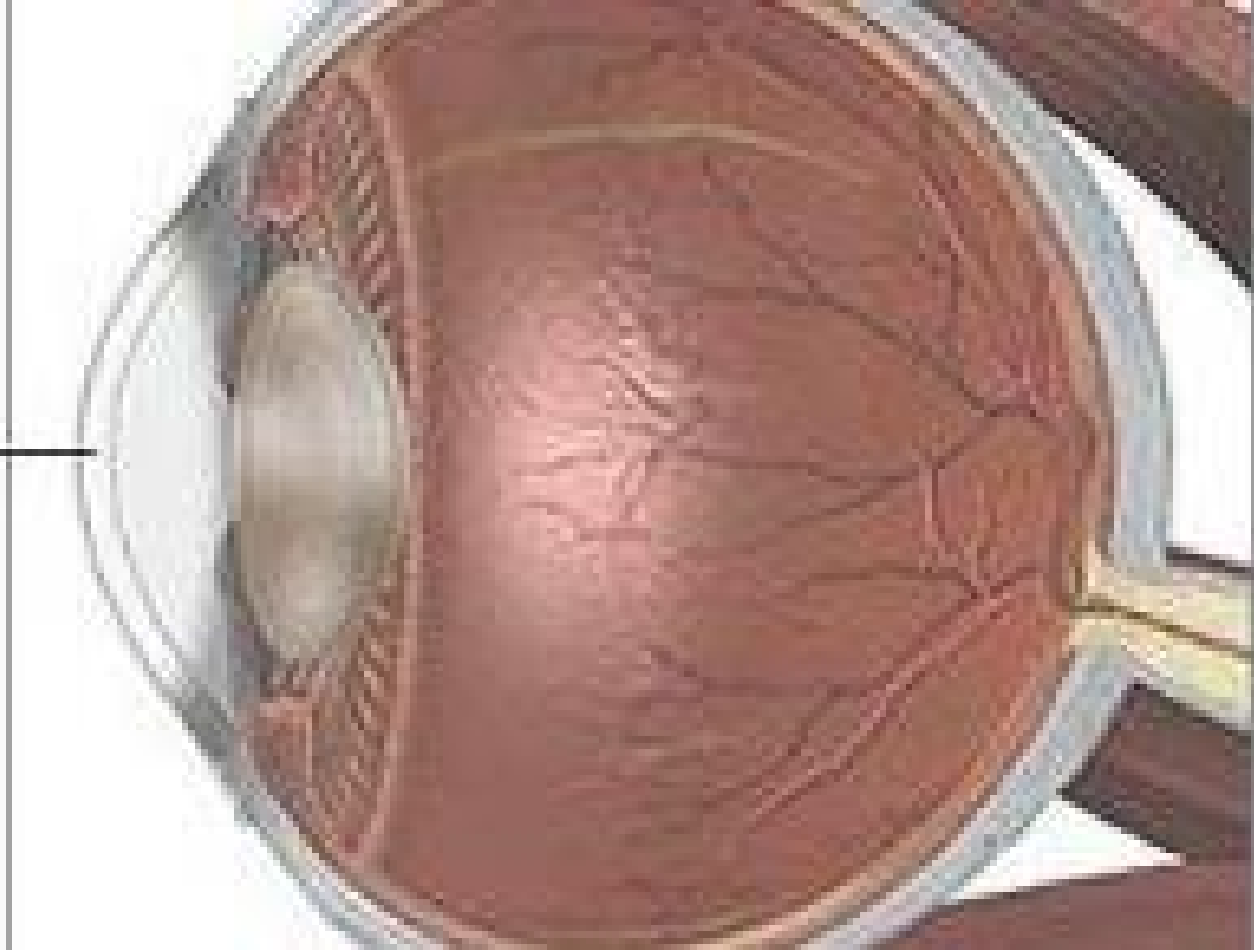

Anatomia oculare

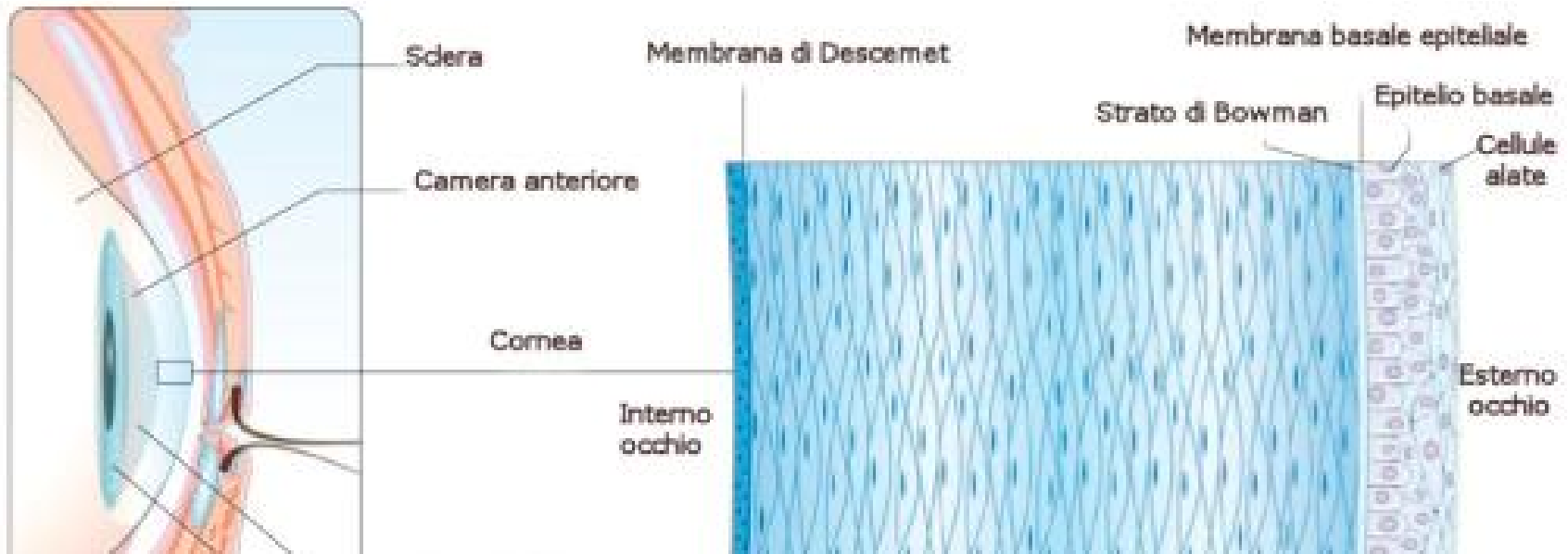


Anatomia oculare

Cornea



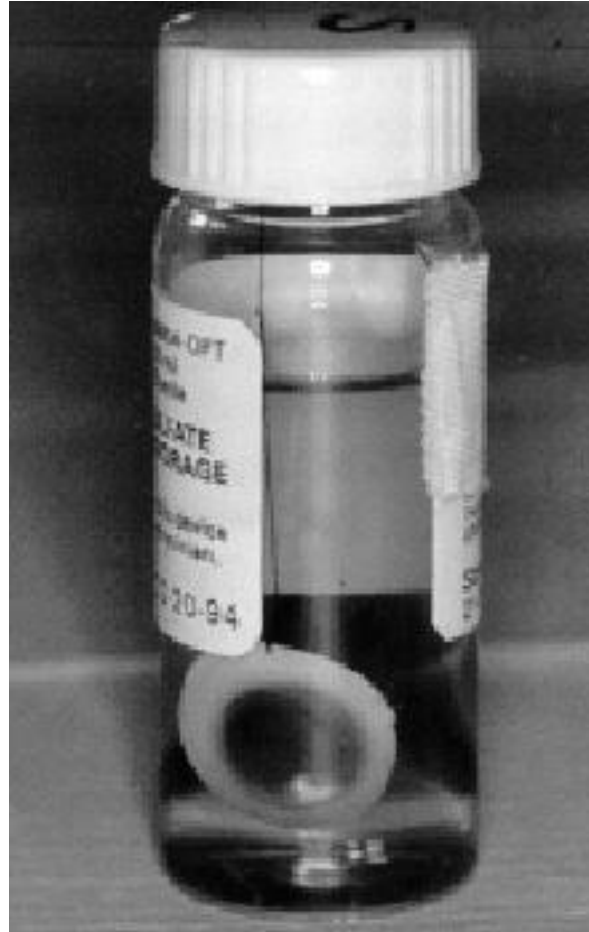Anatomia corneale



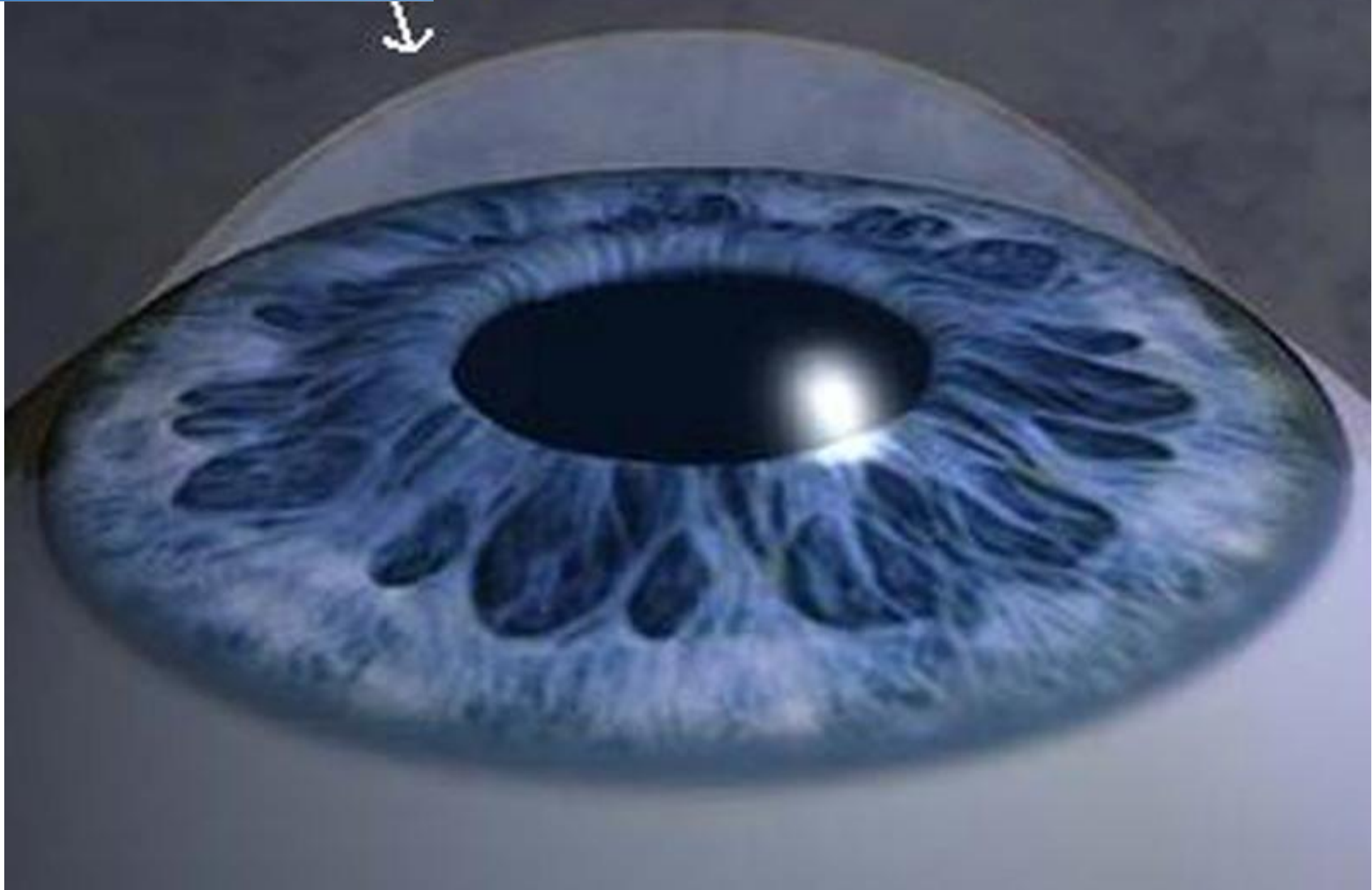
Anatomia corneale



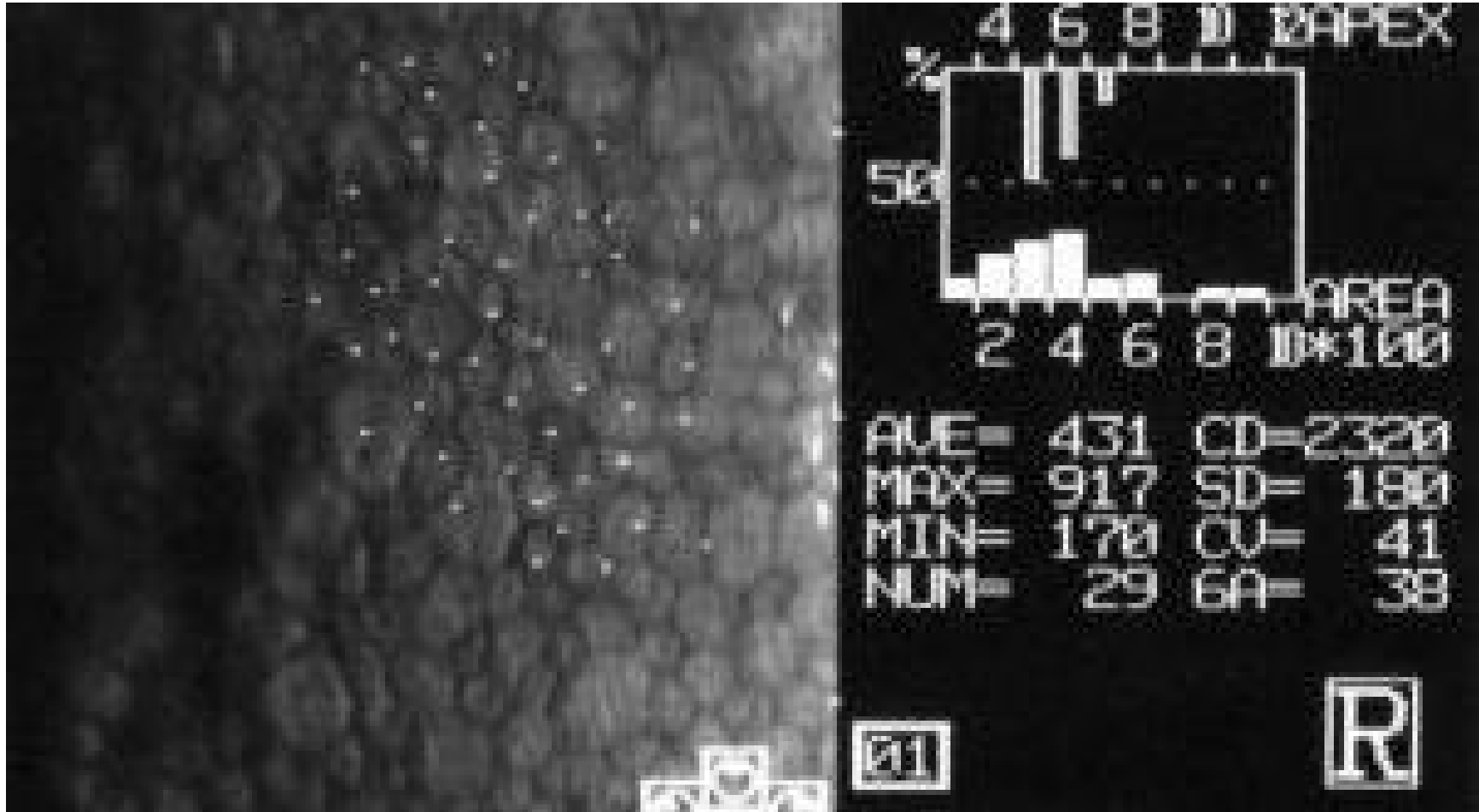
in prelievo sclero-corneale



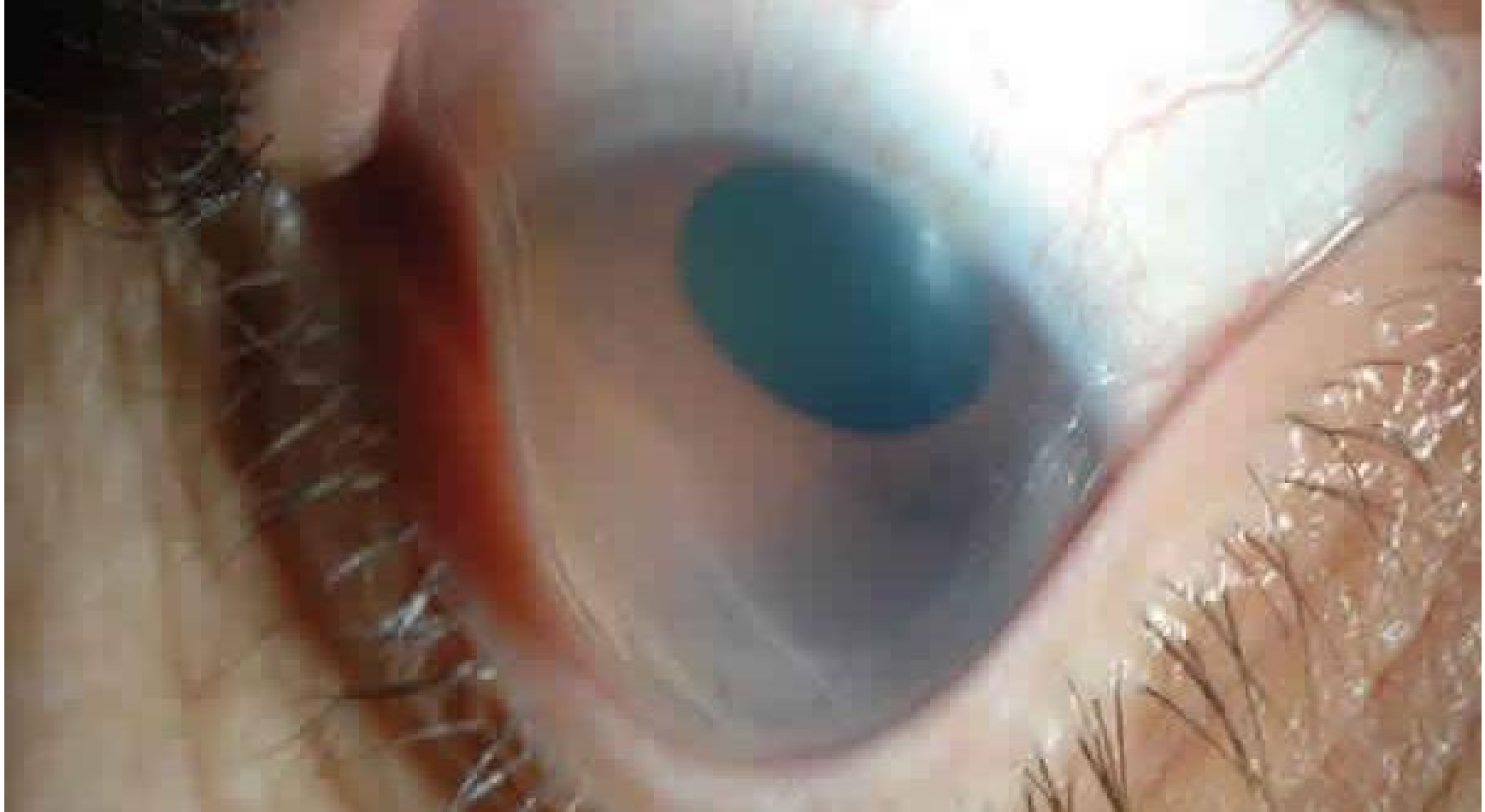IEA



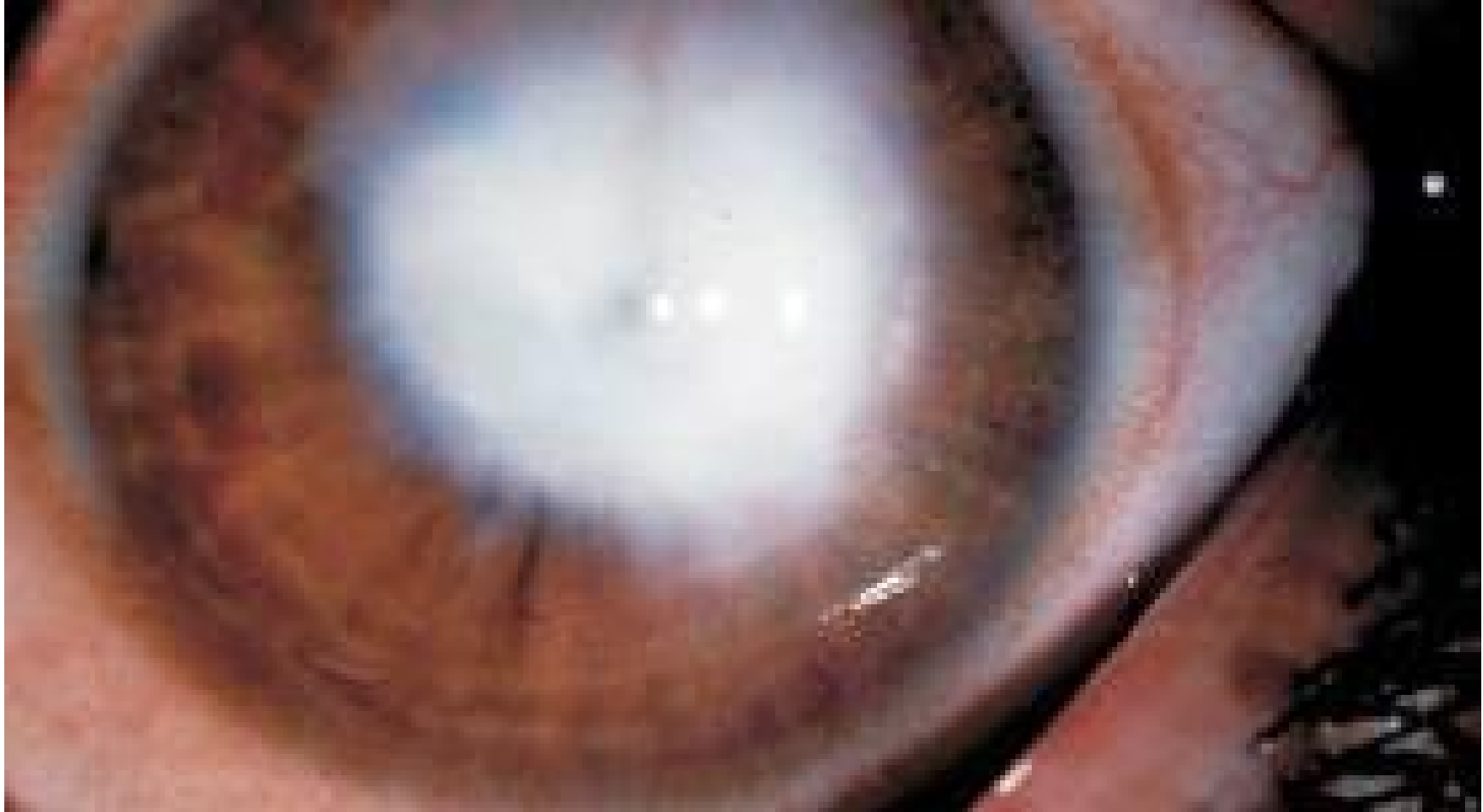La microscopia endoteliale



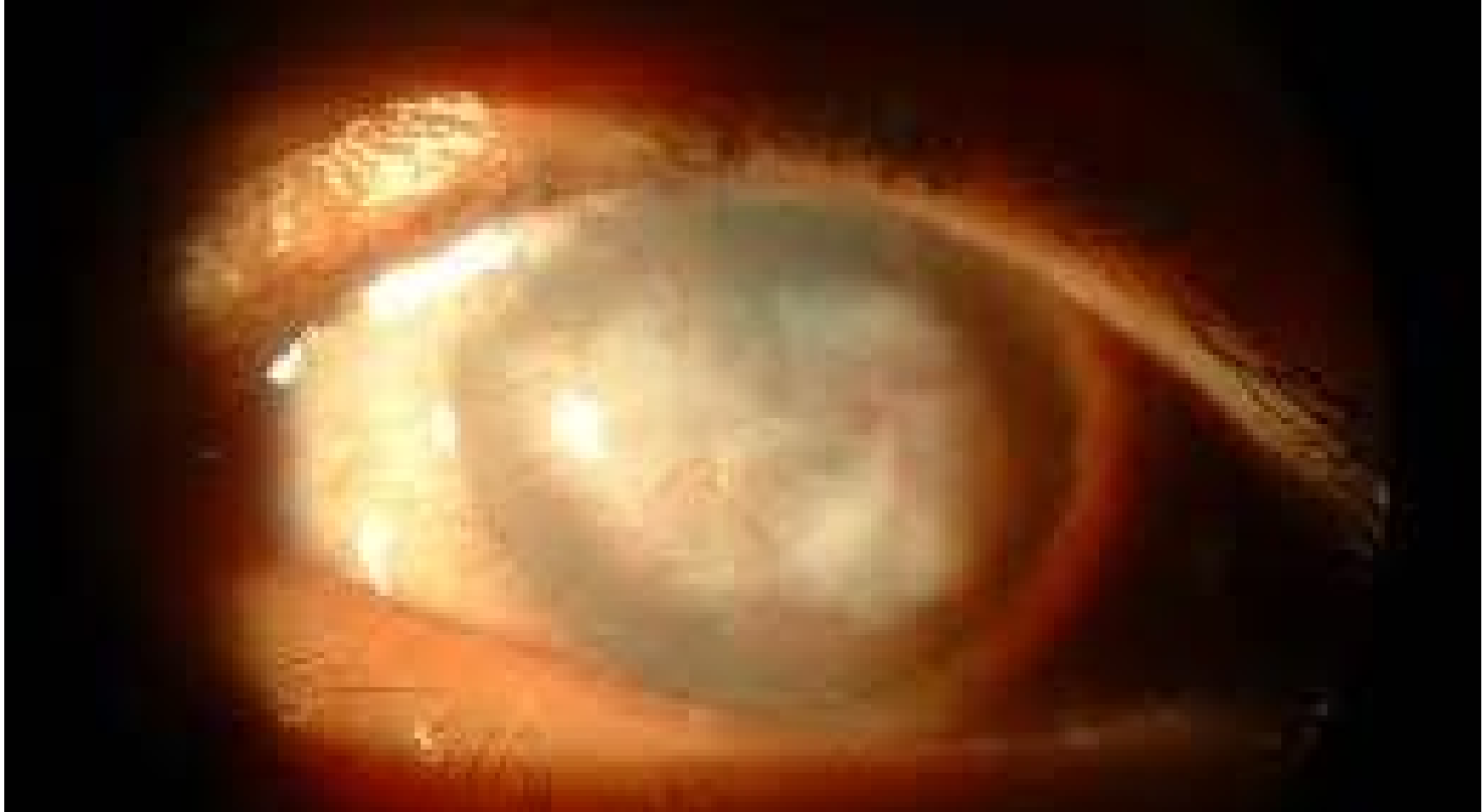Cheratoglobo



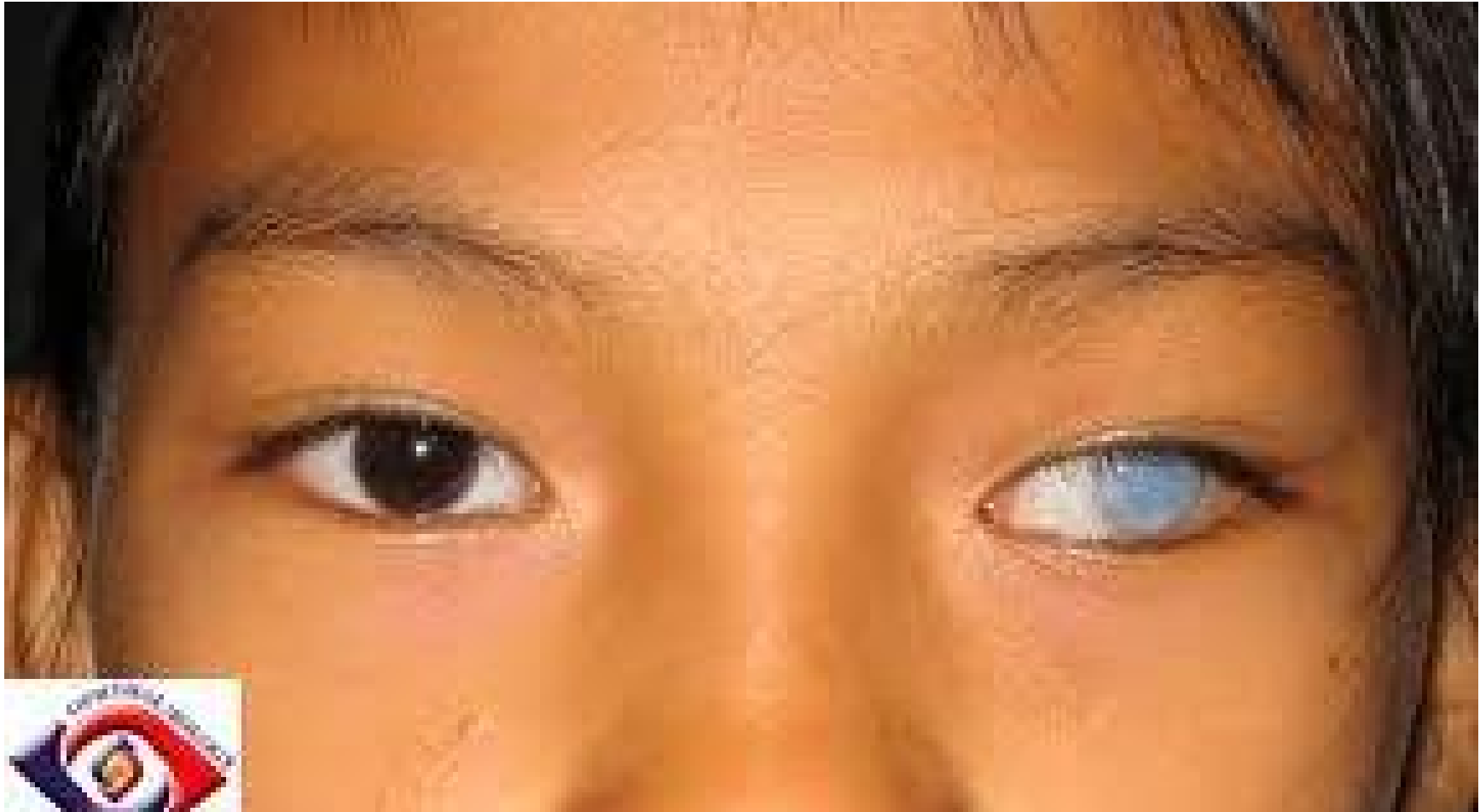Leucoma corneale



Leucoma corneale



scompenso corneale



Trapianto di cornea



Anello sclero-corneale

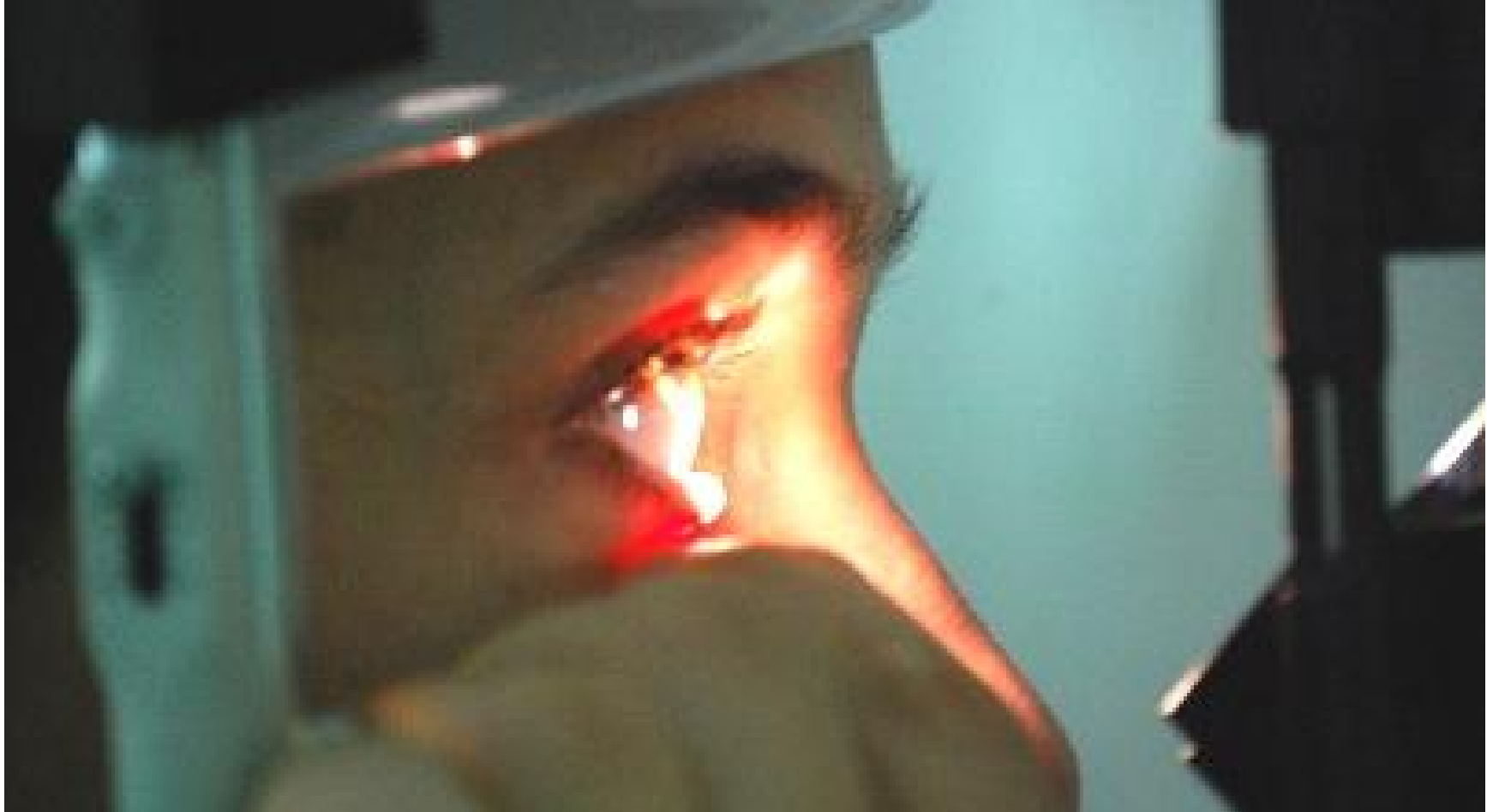

La nostra catena umana



Centro Nazionale Trapianti

Leucoma corneale






*Your complimentary
use period has ended.
Thank you for using
PDF Complete.*

[Click Here to upgrade to
Unlimited Pages and Expanded Features](#)

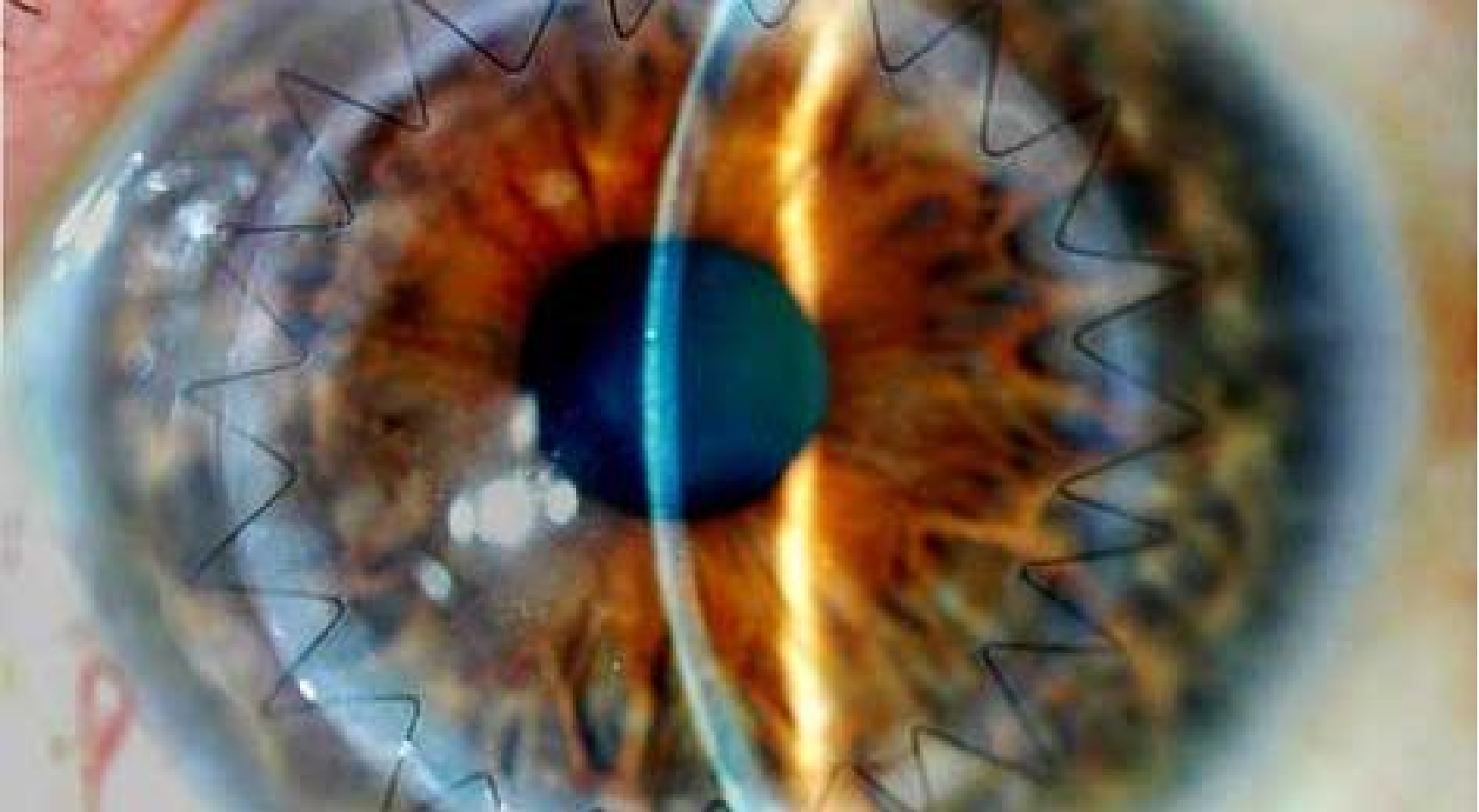
Il trapianto è vita



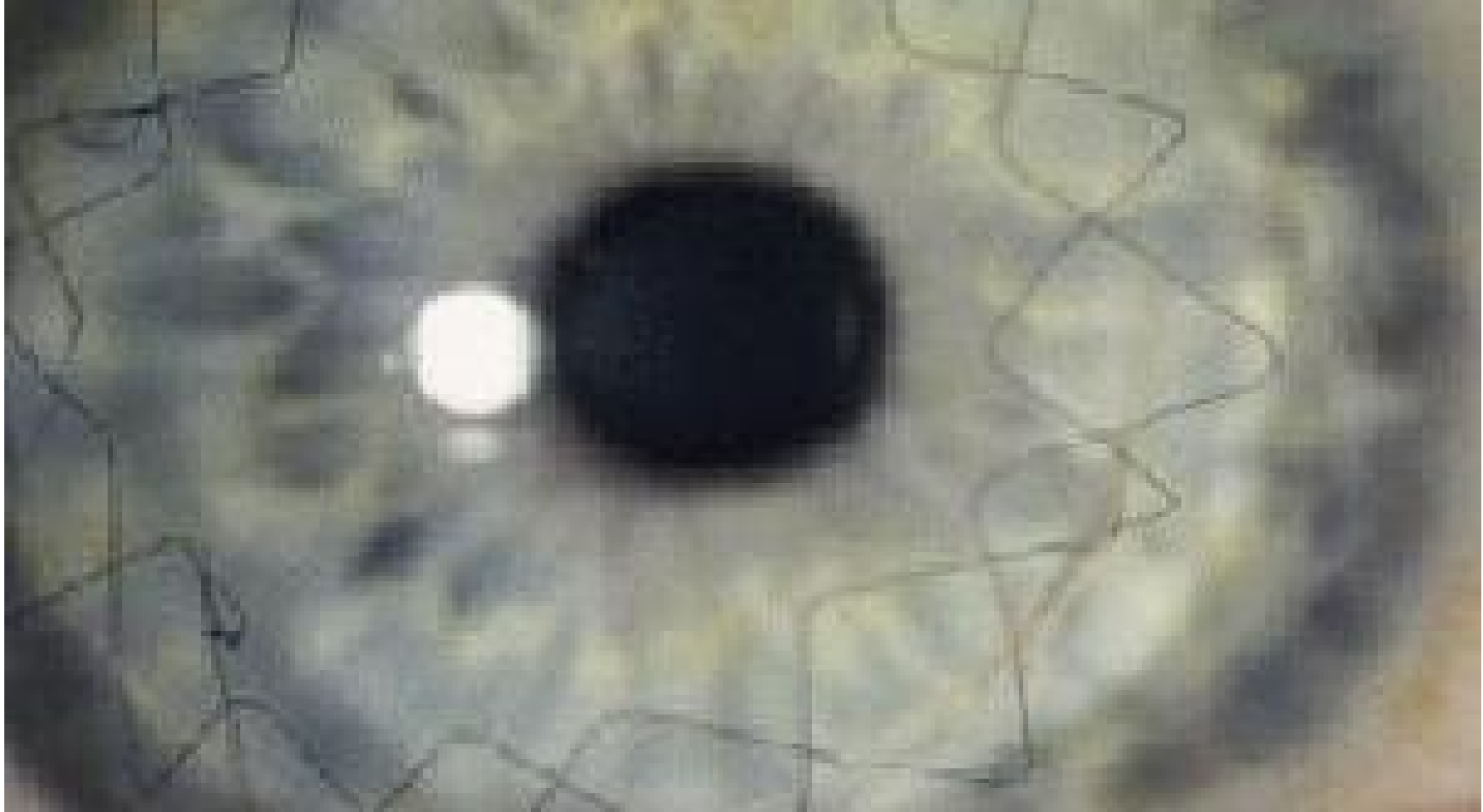no per il prelievo sclero corneale



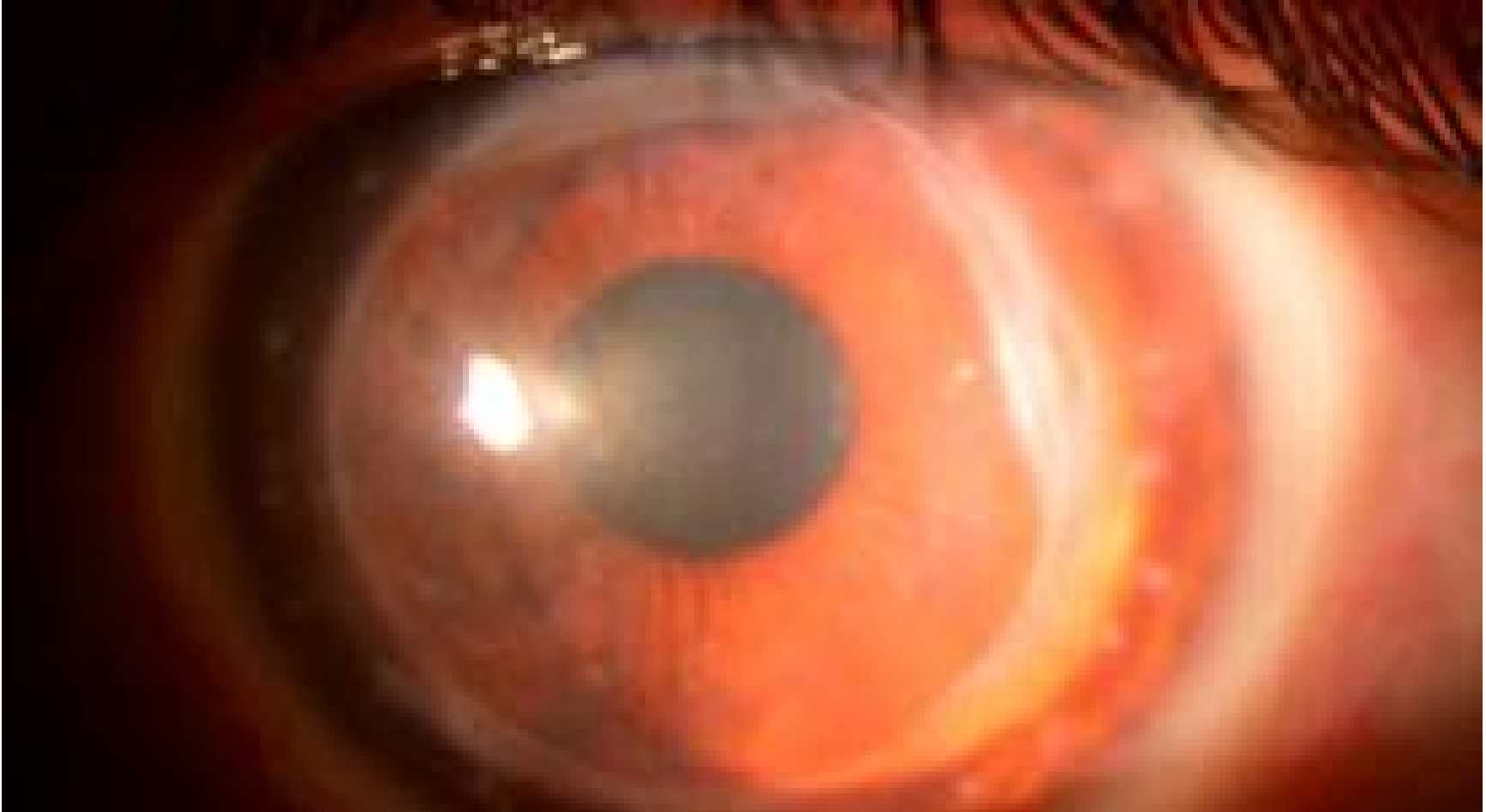L innesto corneale



Dettaglio di KP con sutura



Dettaglio di KP a sutura rimossa



Oltre la vita





*Your complimentary
use period has ended.
Thank you for using
PDF Complete.*

[Click Here to upgrade to
Unlimited Pages and Expanded Features](#)

Lavoro di squadra

